Mary Jo Wohlers, RN BSN 12-04-09

PERICARDIAL TUBERCULOSIS

Presentation:

- 50 y/o female, immigrated from Cambodia 1989. Non-smoker, no known heart problems
- Presented @ the ER w/ 1-2 wks cough, SOB, chest pain on inspiration, febrile, dizziness, some weakness and some weight loss
- Echo revealed small pericardial effusion without tamponade
- CT of chest revealed small pleural effusion with 7mm RUL nodule.

History

- Pt admitted to hospital with DX of respiratory insufficiency, R/O pneumonia, anemia and aortal pulmonary adenopathy
- Ejection fraction was 60%
- Moderate aortic regurg by ECHO
- S1 and S2 were normal without rub or gallop

History

- Echo revealed small circumferential pericardial effusion, without tamponade
- CX-Ray showed cardiomegaly and CHF
- B/P: 105/65
- One sputa collected: Smear neg/ Culture positive for MTC

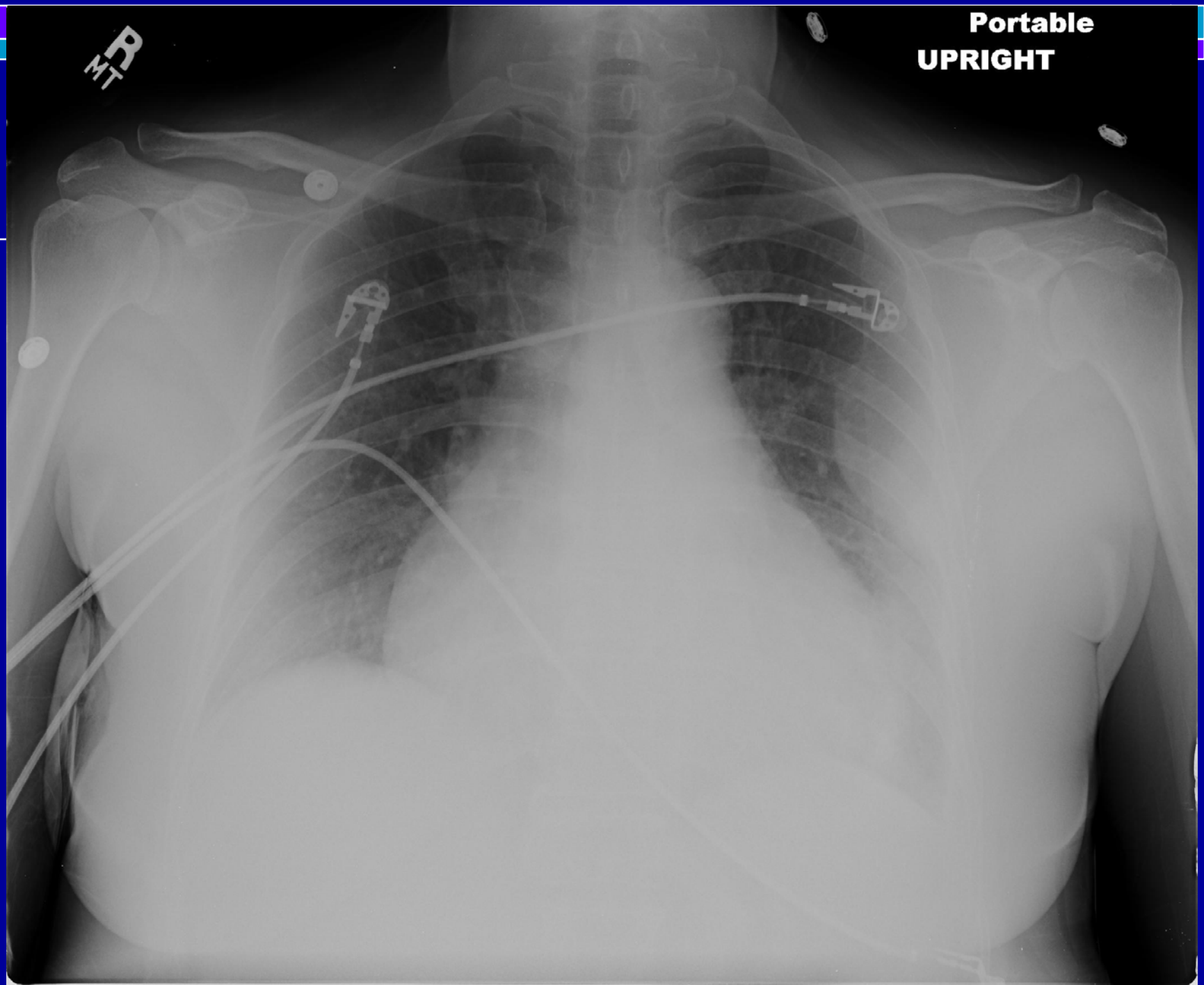
R
Portable
UPRIGHT

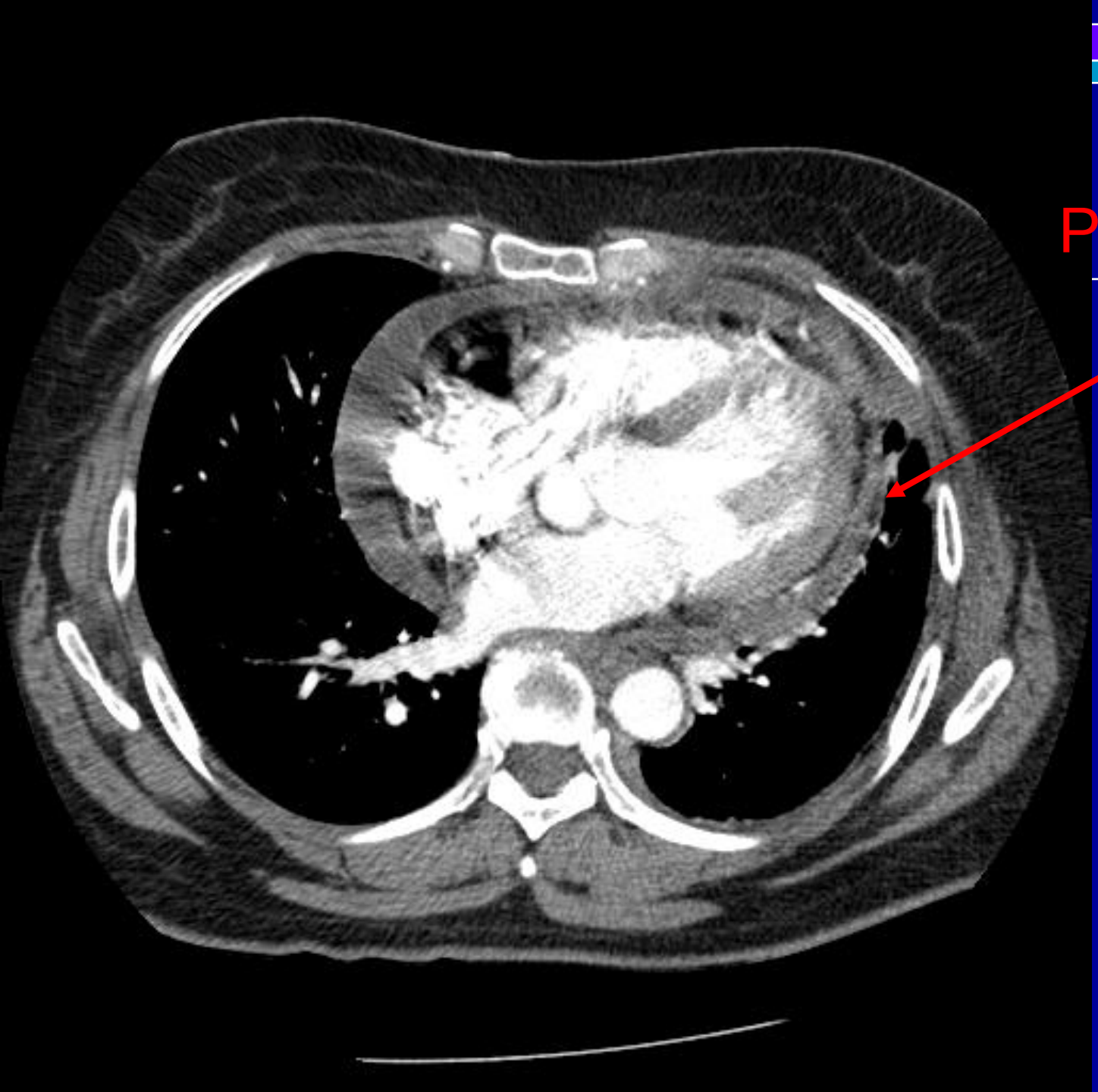

Pericardium

Procedure:

- Creation of pericardial window via L anterior thoracotomy to drain pericardial effusion and bx the pericardium
- Findings included significant adhesions along the diaphragmatic and lateral surface. The pericardium was thickened and inflamed.
- Inflammatory fibrous patch over the L ventricle.

- 250 ml of cloudy, serous fluid was evacuated
- A normal pericardial sac holds 15-50 ml of fluid
- Thickened pericardium on an echo are suggestive of infective etiology
- Pericardium: Smear neg/Culture pos for MTC

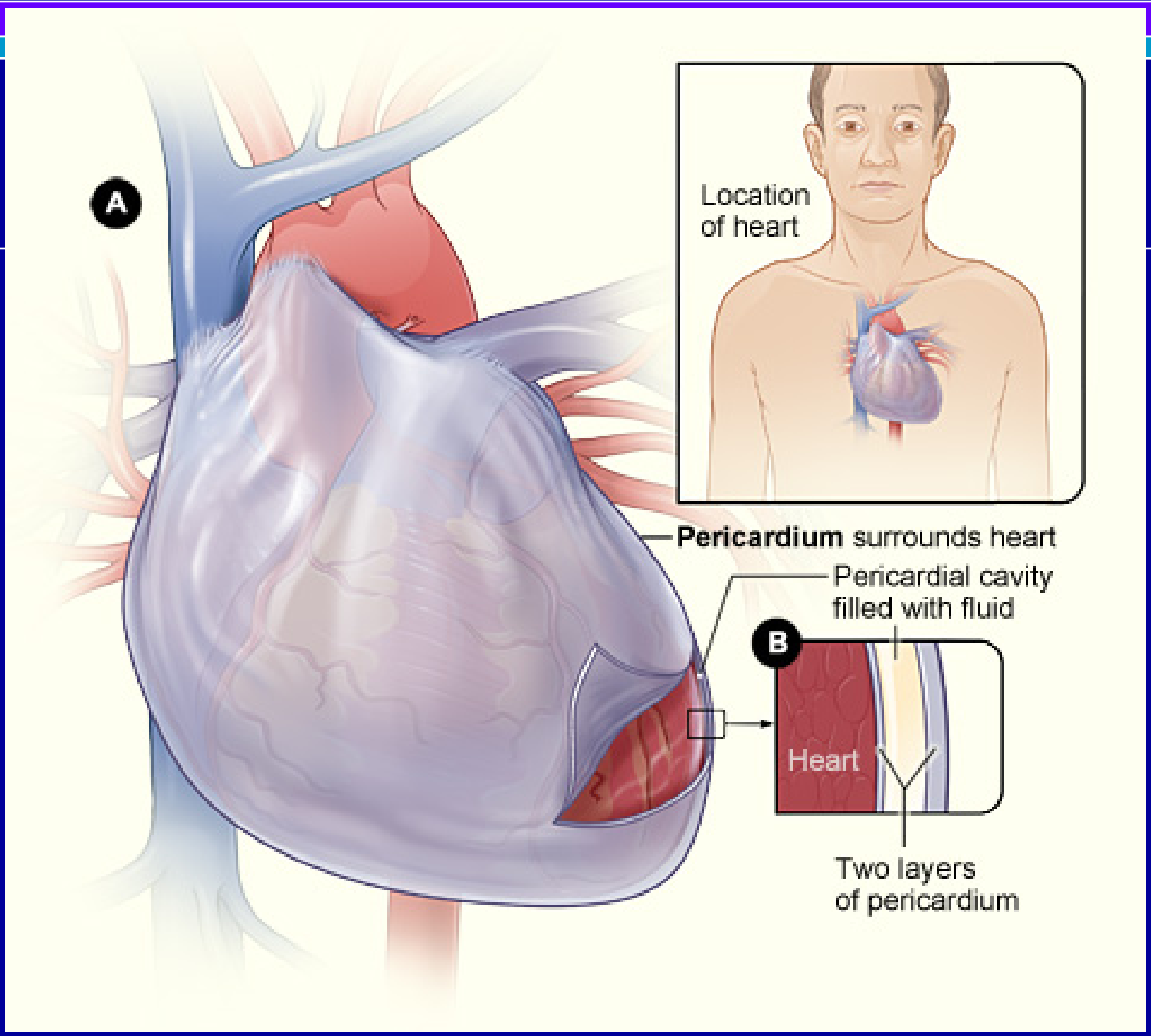
A
Location of heart
Pericardium surrounds heart
Pericardial cavity filled with fluid
B
Heart
Two layers of pericardium

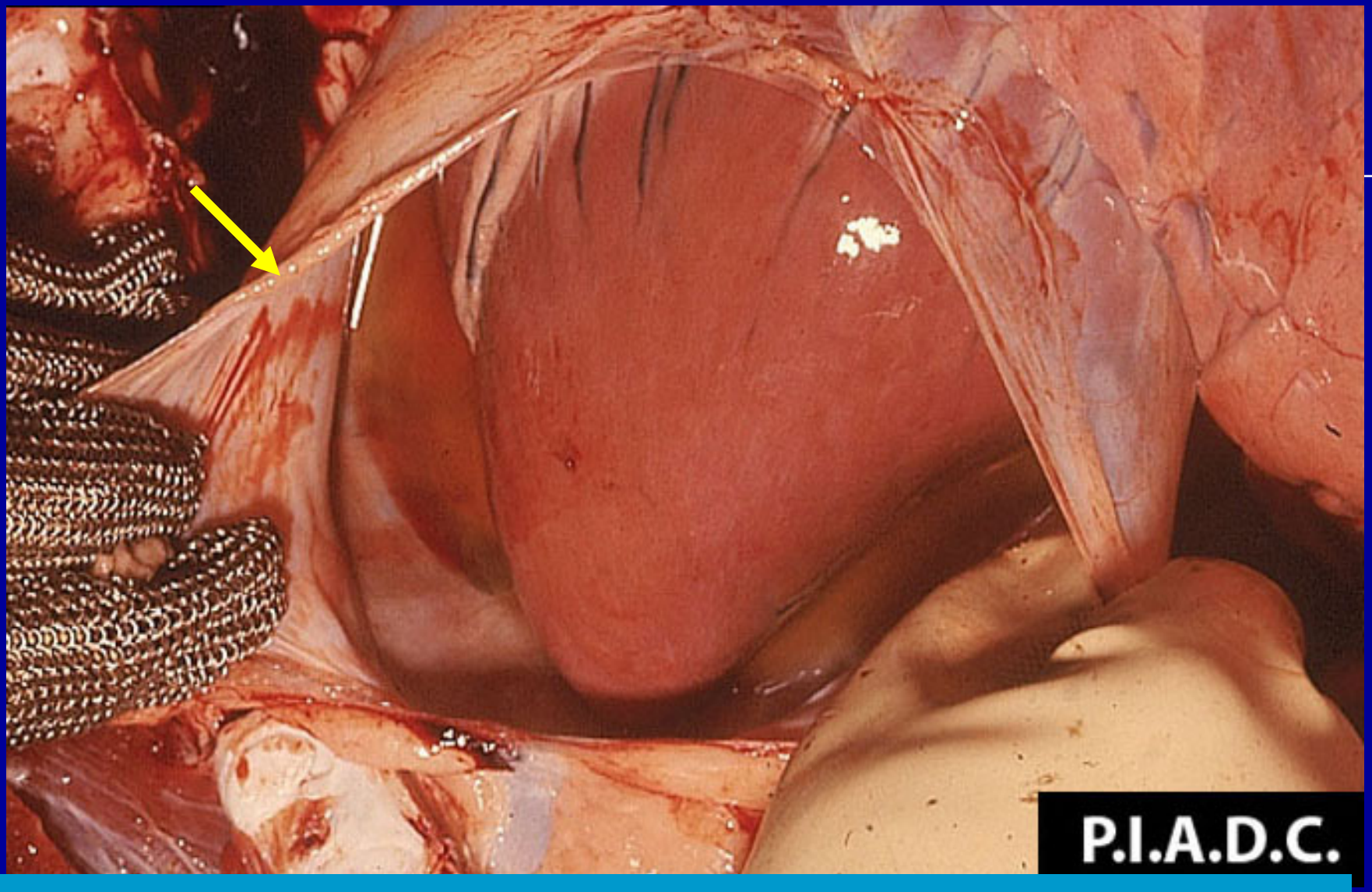

Note how this pericardium is easily removed from the surface of the Heart

Pericardial TB is defined by:

- Pericardial tissue or fluid culture positive for MTB
- Pericardial bx specimens demonstrating acid-fast organisms, caseating granulomata, or both
- Extra pericardial bacteriologic or histologic evidence of active TB in conjuction with major pericardial effusion or thickening by echo

How does TB get to your heart?

- TB pericarditis usually develops by retrograde spread from peribronchial, peritracheal or mediastinal lymph nodes
- It may also develop from a focus in the lung, spine and sternum
- TST may be negative in as many as 30% w/ TB, owing to anergy.

Good to know:

- Pericardial fluid aspiration is important for dx
- Acid-fast bacilli are rarely found in pericardial effusions
- Cultures of pericardial fluid are positive in only 50% of cases
- Pericardial TB must be dx early because cardiac tamponade can occur in the acute phase and constrictive pericardia may develop later

Constrictive Pericarditis:

- **pericarditis:** Scarring of the pericardial sac. This limits the ability of the heart to function because it cannot dilate completely, so filling is impaired. Infections can be the cause.
- The constriction occurs slowly over time and causes shortness of breath on exertion and a decreased ability to exercise. Swelling in the legs and the abdomen may exist because it is difficult for blood to return to the heart, and fluid leaks out into the tissues.

Readmitted to hospital

- Pt began having nausea and intermittent vomiting during first two weeks of anti-TB meds.
- Pt was taking R,I, P,E pansuscep and her Ethambutol was d/c. The nausea persisted and she was given Zofran, and Phenergan only slight improvement in sx’s

- Pt was also taking Lasix 20 mg q day
- Pt began to notice edema in her ankles
- Weight 6/5: 175 lbs, 6/18: 176 6/24: 192.5
- Edema lumbar/sacral
- Appeared uncomfortable, too nauseated to swallow meds, reports no appetite x 3 days
- PHN called 911

Hospital course

- Admitted for volume overload and nausea
- BNP of 458
- Chest CT: no change in 7mm RUL nodule, moderate R pleural effusion w/ R basilar atelectasis, small L pleural effusion w/ mild L basilar atelectasis
- Mild pericholecystic fluid and small amount abdominal ascites

Brain Natriuretic Peptide

- BNP assay is a 15-minute blood test that is highly sensitive and fairly specific for diagnosing heart failure and is useful in evaluating suspected heart failure in outpatients and in emergency rooms.

BNP:

- BNP, a cardiac neurohormone, was first discovered in the brain of pigs. In humans, the main source of BNP is the ventricles of the heart. BNP is secreted in response to increased ventricular volume and pressure. Circulating BNP levels increase in proportion to the severity of the disorder, and is detectable with minimal clinical symptoms.

BNP continued:

A high value of BNP in the blood indicates:

- An increased amt of fluid or high pressure inside the heart
- A higher chance of death in people with heart failure
- Or may indicate early heart failure in pts on renal dialysis

Brain Natriuretic Peptide

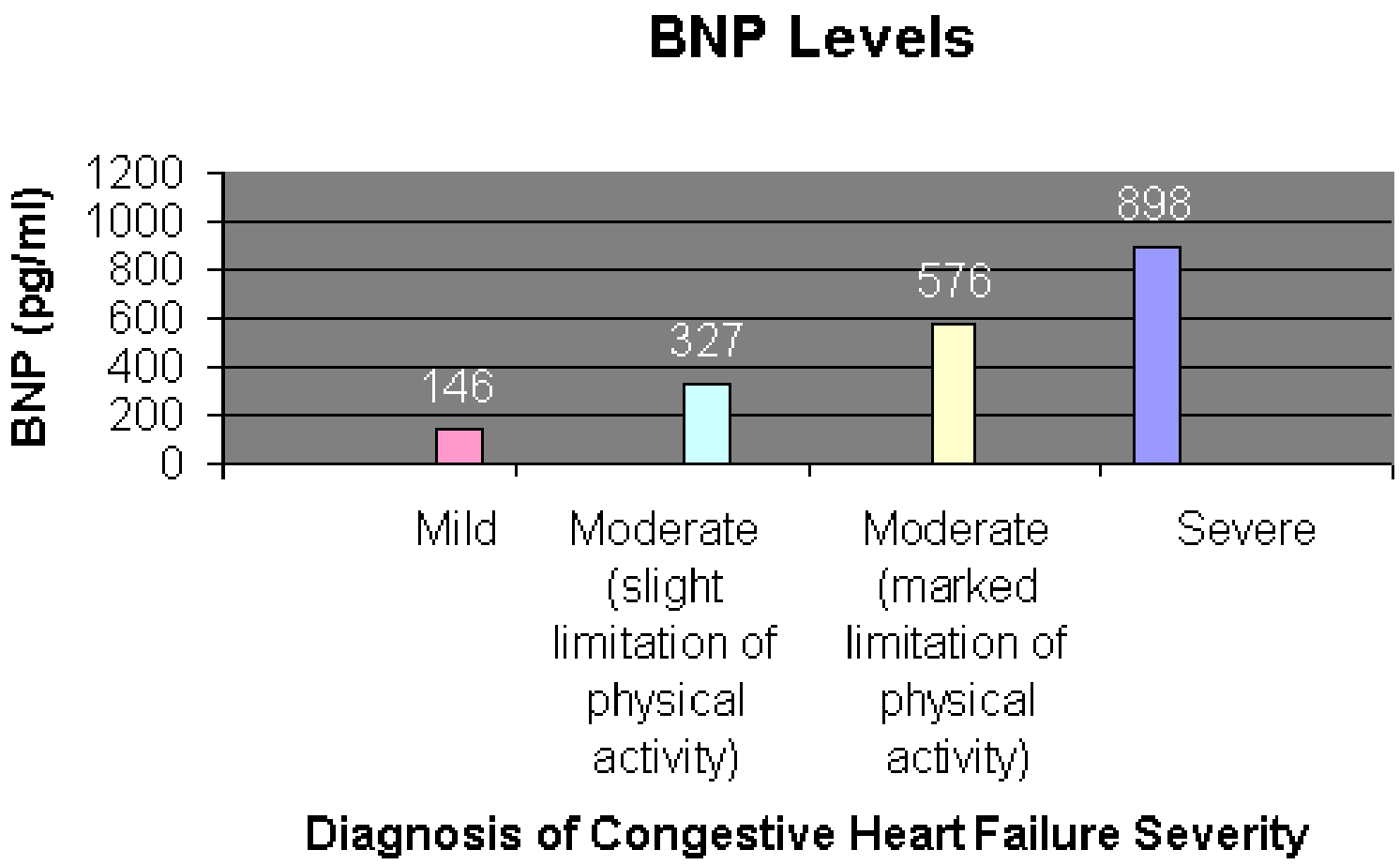

Procedure during 2nd admission:

- R Thoracentesis performed w/ 500 ml of fluid withdrawn
- 2 days later Chest X-Ray shows small stable R pleural effusion, no congestive failure
- Progression of small amt abdominal ascites
- Pt discharged after 1 week in hospital on Lasix 40mg qd, K+ 20 mEq Wt: 184.0 lbs

Pericardial TB Facts:

- TB is responsible for approx 70% of cases of large pericardial effusion and most cases of constrictive pericarditis in developing countries.
- In industrialized countries TB accounts for only 4% of pericardial effusion and an even smaller proportion of constrictive pericarditis

TB Pericarditis

- Extrapulmonary TB occurs in 15-20% of pts w/ TB
- TB pericarditis is seen in 1-8% of these pts.
- TB pericarditis can present w/ recurrent pericardial effusion w/out any hx or sx of TB

Calcified Pericardium

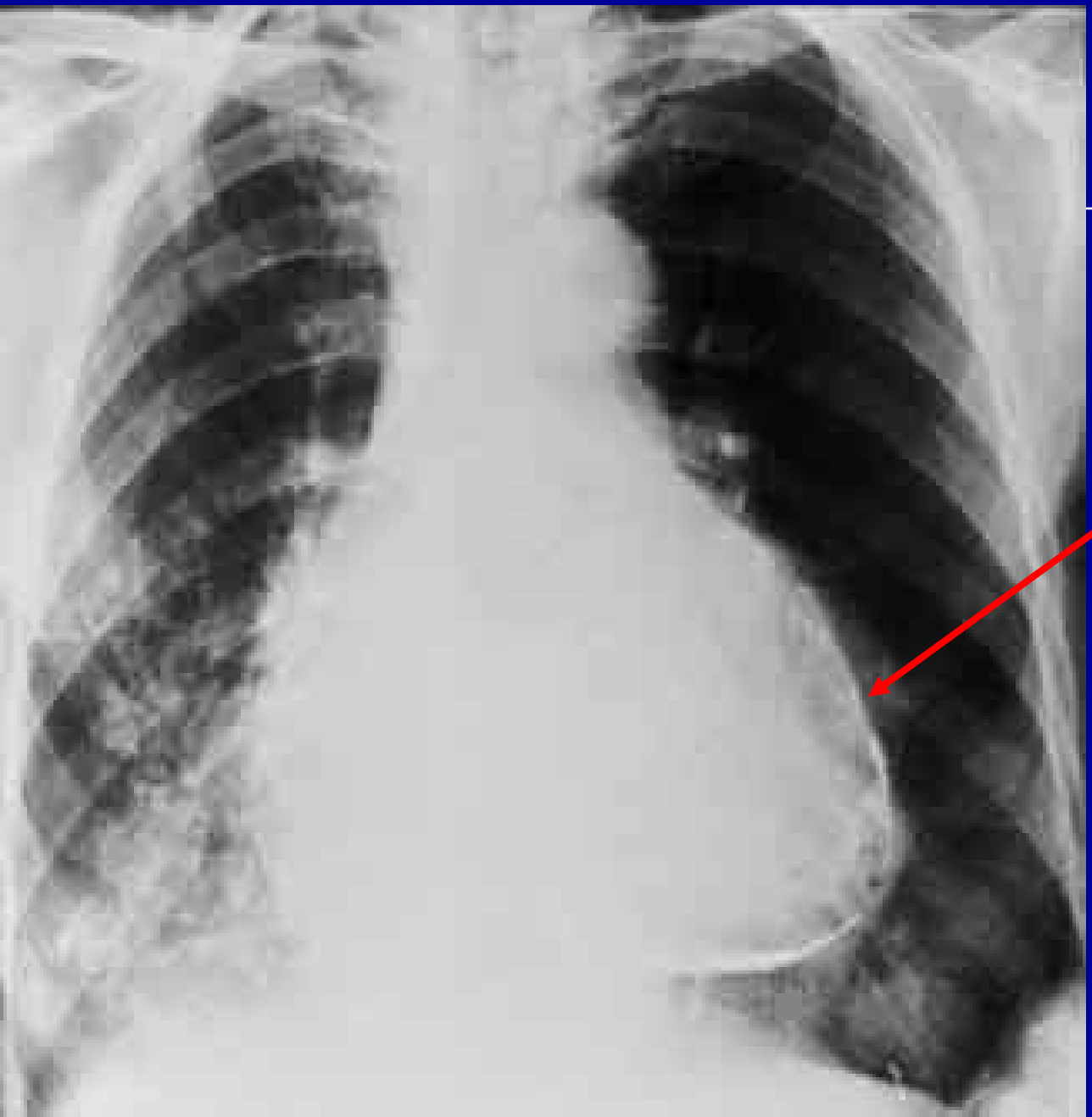

Calcified Pericardium

Pericarditis

- Post mortem specimen of constrictive pericarditis
- Note the thickened pericardium attached to the heart muscle

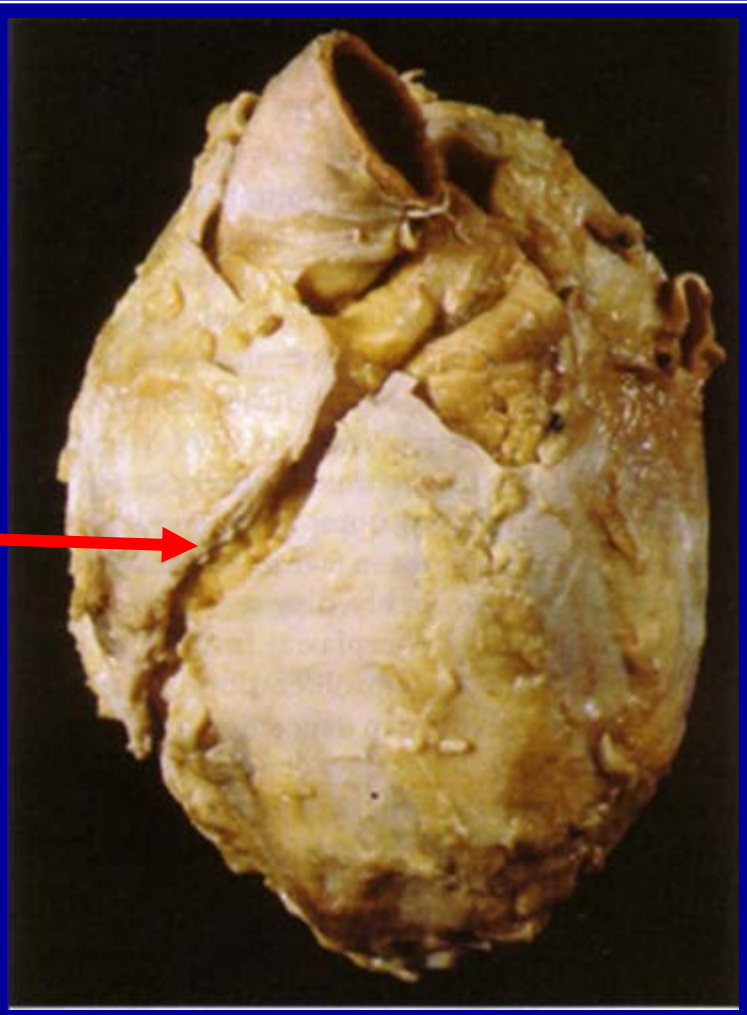

TB Pericarditis:

- TB pericarditis is a dangerous disease with a mortality of 17%-40%
- It is uncertain whether adjunctive corticosteroids are effective in reducing mortality or pericardial constriction

Pericarditis/ Surgical Intervention

- Surgical resection of the pericardium is indicated for those with calcific constrictive pericarditis

Or

- Patients with persistent signs of constriction after 6 weeks to 8 weeks of anti-TB tx in patients with noncalcific constrictive pericarditis

Treatment

- Standard anti-tb medications
- Corticosteroids help in rapid improvement of sx's and reduce mortality (4% vs. 11%) reduced the need for pericardectomy (21% vs.30%), but do not influence the resolution of pericardial effusion and do not reduce the risk of constrictive pericarditis

AJRCCM 2003; 167: 647-648

The patient today:

- Lab work is normal
- Weight has climbed steadily and she now weighs 197.4 lbs
- CXR: 3mm calcified granuloma R mid lung field. Heart is normal size! No pleural effusion or vascular congestion
- C/O chest pressure and tightness, no SOB

Summary

- Tuberculosis of the pericardium is not common in the USA, but is very common in Africa
- Aspiration of the pericardial fluid is therapeutic, usually AFB smear negative, but culture positive in ~ 50%
- Complication of constrictive pericarditis which may require surgical removal of the pericardium

Contact Information

- Mary Jo Wohlers, RN BSN
- Public Health Nurse, TB Case Manager
- Fairfax County Health Department
- 703-388-1357
- Mary.wohlers@fairfaxcounty.gov