All That Wheezes… is Respiratory Distress!

Benjamin Lawner, DO, EMT-P, FAAEM
Assistant Professor, Emergency Medicine
University of Maryland School of Medicine
Deputy Medical Director, Baltimore City Fire Department

Objectives

- Identify signs and symptoms of COPD
- Identify patients in acute pulmonary edema
- Immediately recognize respiratory failure

See how far we've come…



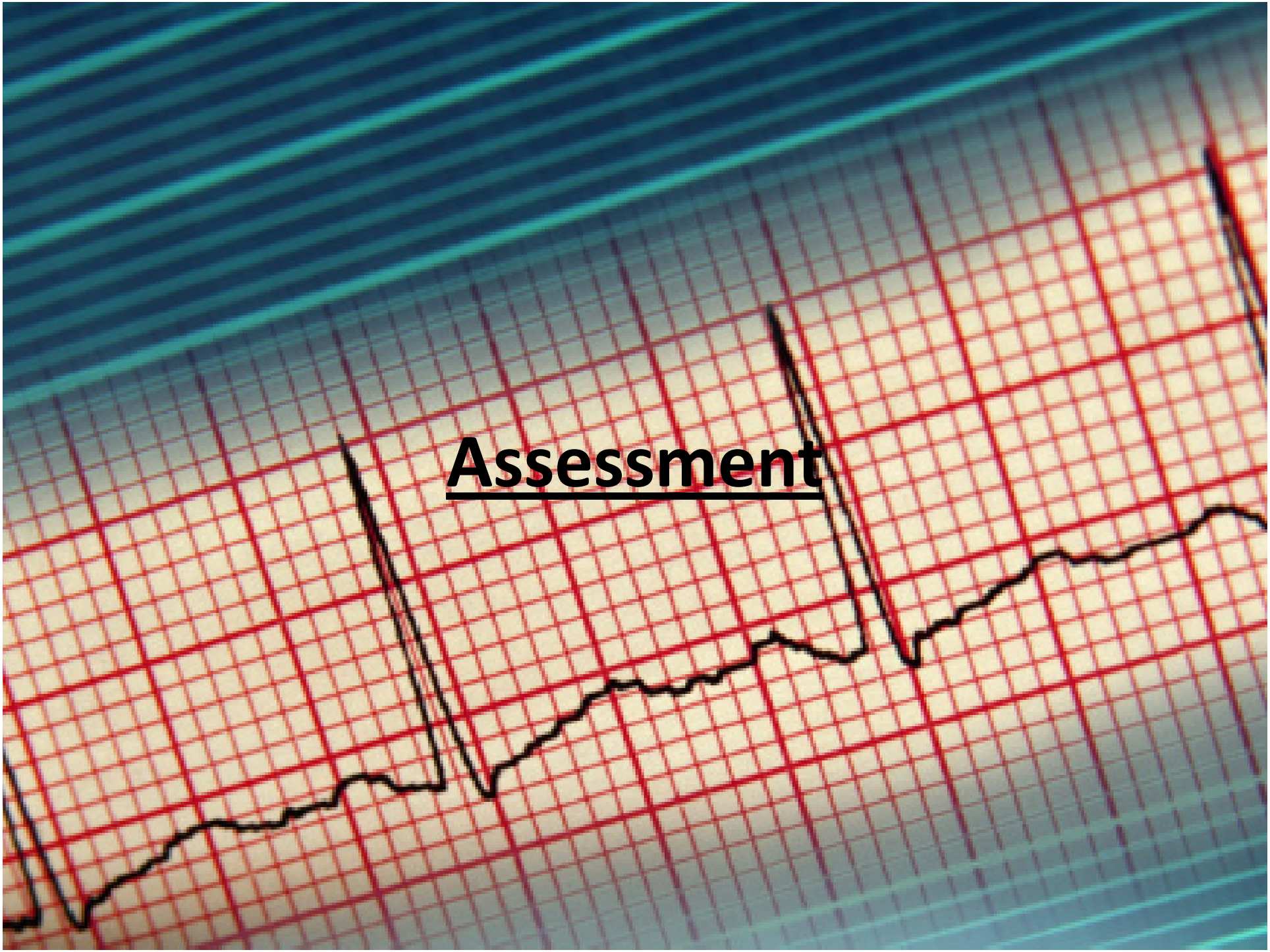

Assessment

Respiratory Distress

- At a glance
- Gauge level of distress
- Work of breathing
- What is the most sensitive indicator ?

Respiratory Distress

- Pulse oximetry
- Respiratory rate
- Respiratory depth
- Presence of retractions

Respiratory Rate

- Single most important indicator of WOB

Respiratory Distress

- Retractions
- Speech
- Accessory muscle use
- Paradoxical breathing
- Silent chest / motionless chest
- Altered mental status

Assessment

- Brain as an end organ
- Hypercapnia
- Hypoxia
- Inadequate perfusion
- C02 “narcosis”

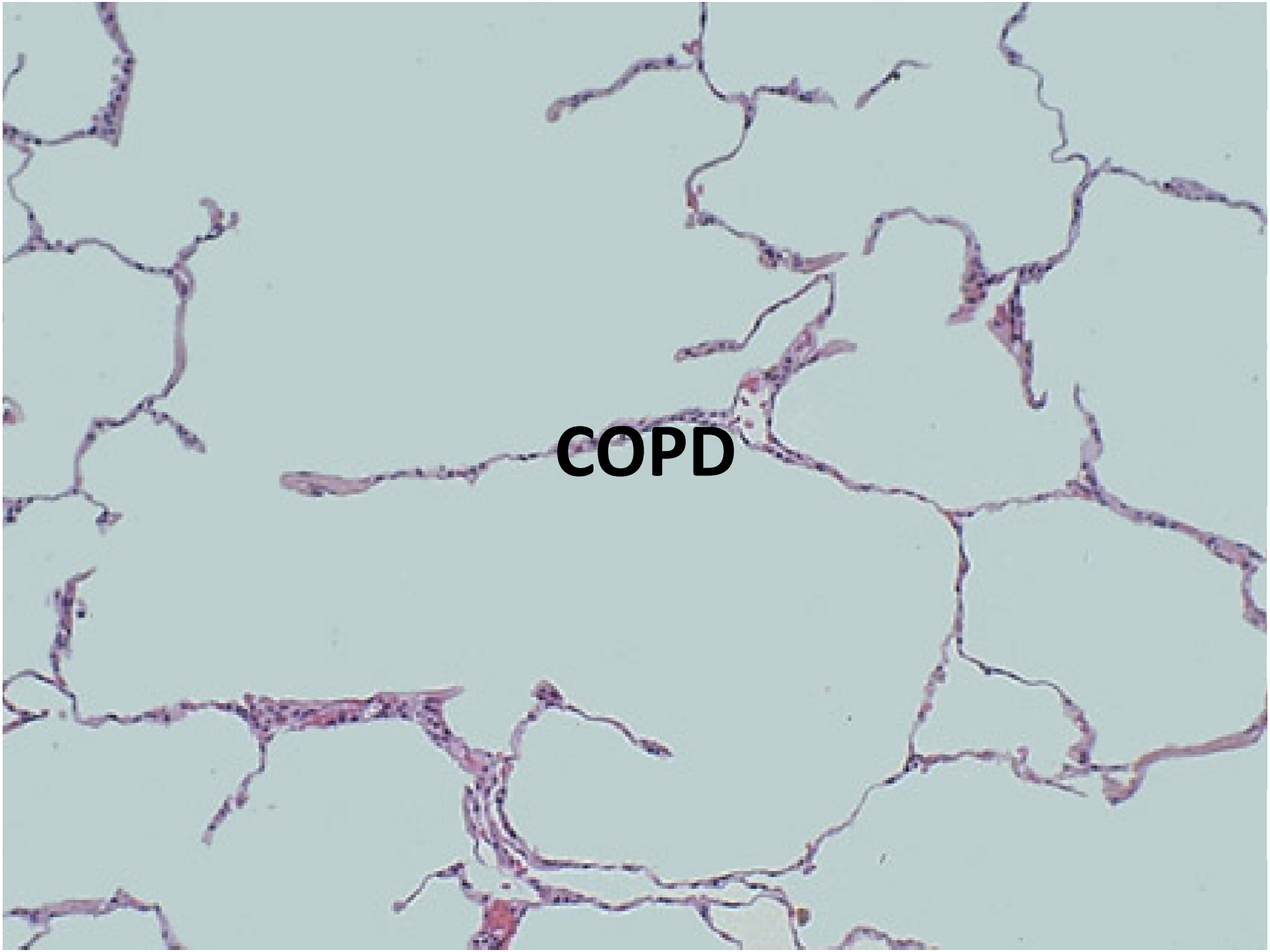
COPD

COPD: History

- Cough, usually productive
- History of multi-year symptoms
- Breathlessness
- Dyspnea on exertion
- History of smoking

COPD: History

- Productive cough progresses to dyspnea
- Frequent pulmonary infections
- Self reported wheezing
- Fatigue

COPD: Assessment

- Poor sensitivity of physical examination
- Hyperinflation
- Wheezing
- Decreased breath sounds
- Hyper-resonance
- Prolonged expiration

COPD: Hyperinflation

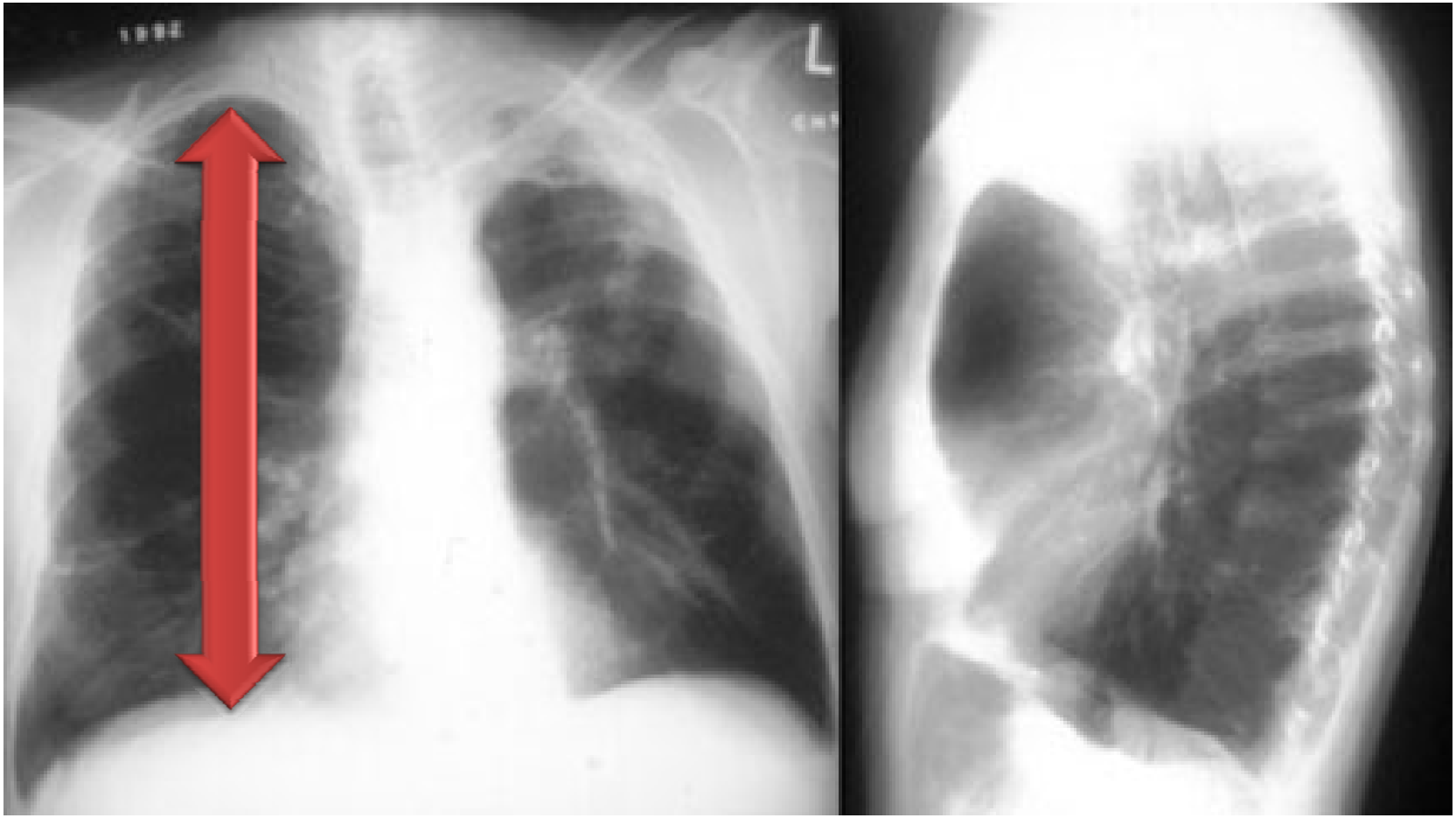

COPD: Hyperinflation

COPD: Structure Tells the Story

COPD: Assessment

- Barrel chest
- Cachexia / wasting
- Distant heart sounds
- Accessory muscle use
- Crackles
- Cor pulmonale

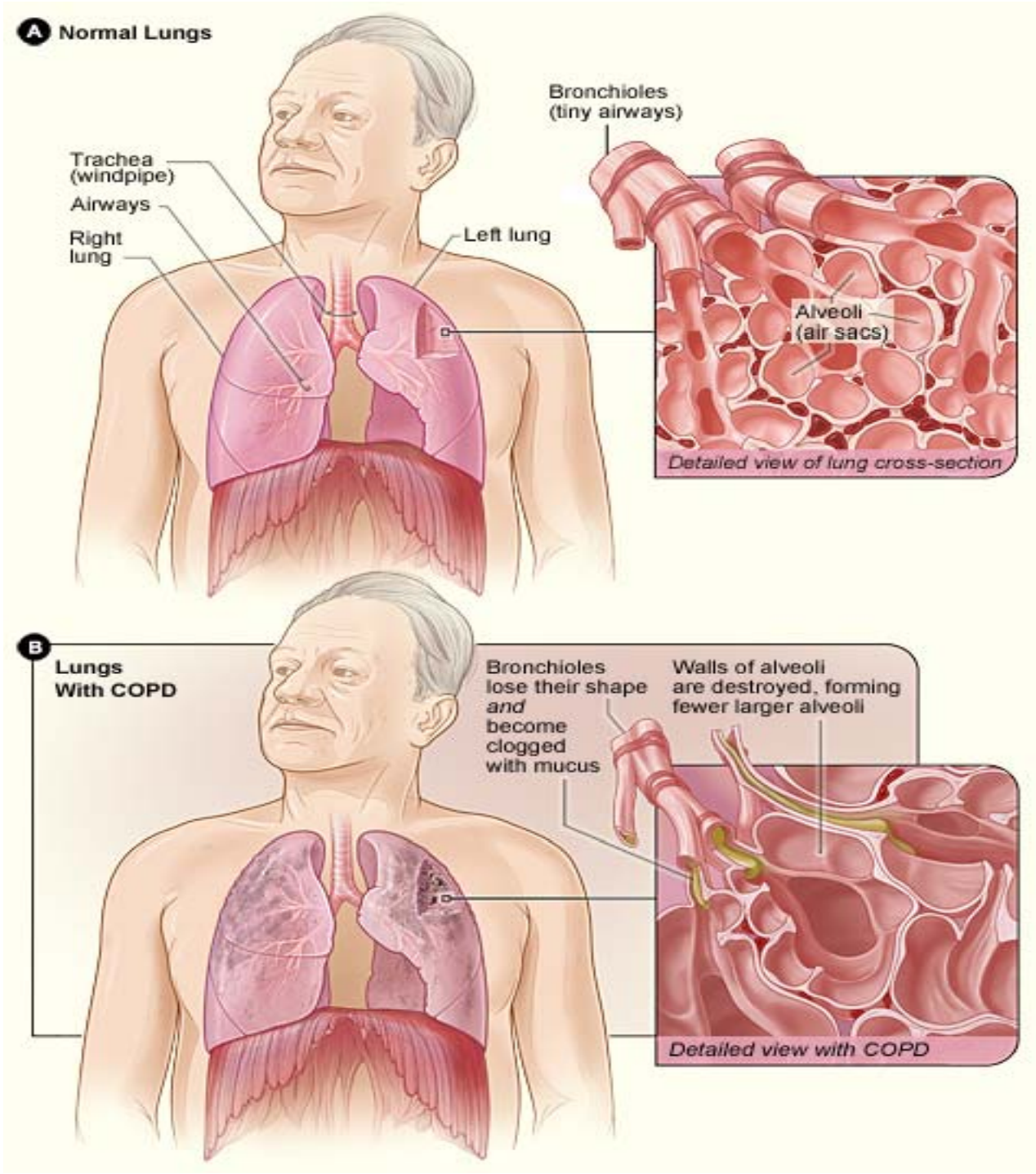
A Normal Lungs
Trachea (windpipe)
Airways
Right lung
Left lung
Bronchioles (tiny airways)
Alveoli (air sacs)
Detailed view of lung cross-section
B Lungs With COPD
Bronchioles lose their shape and become clogged with mucus
Walls of alveoli are destroyed, forming fewer larger alveoli
Detailed view with COPD

COPD: ECG Changes

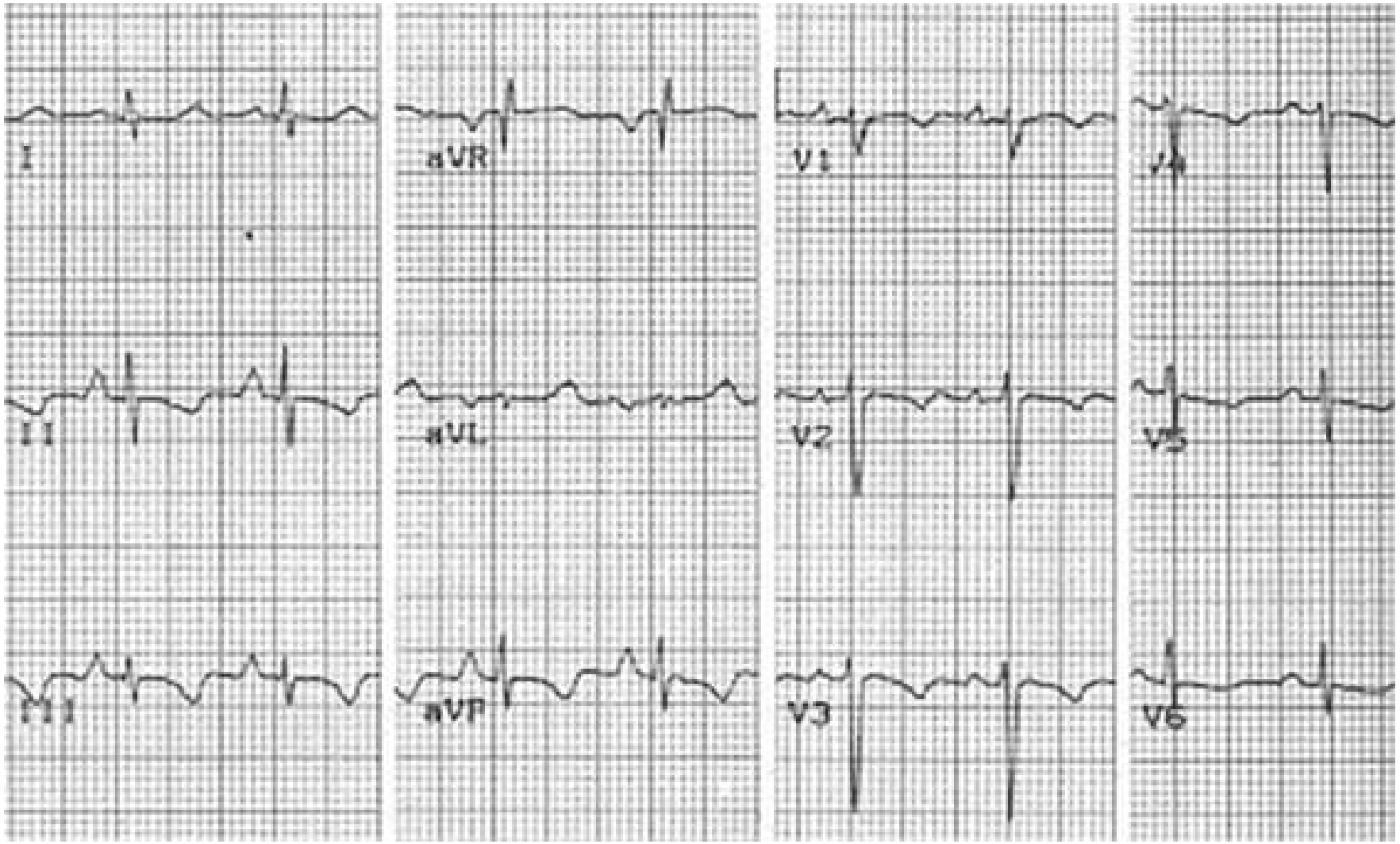

COPD: ECG Changes

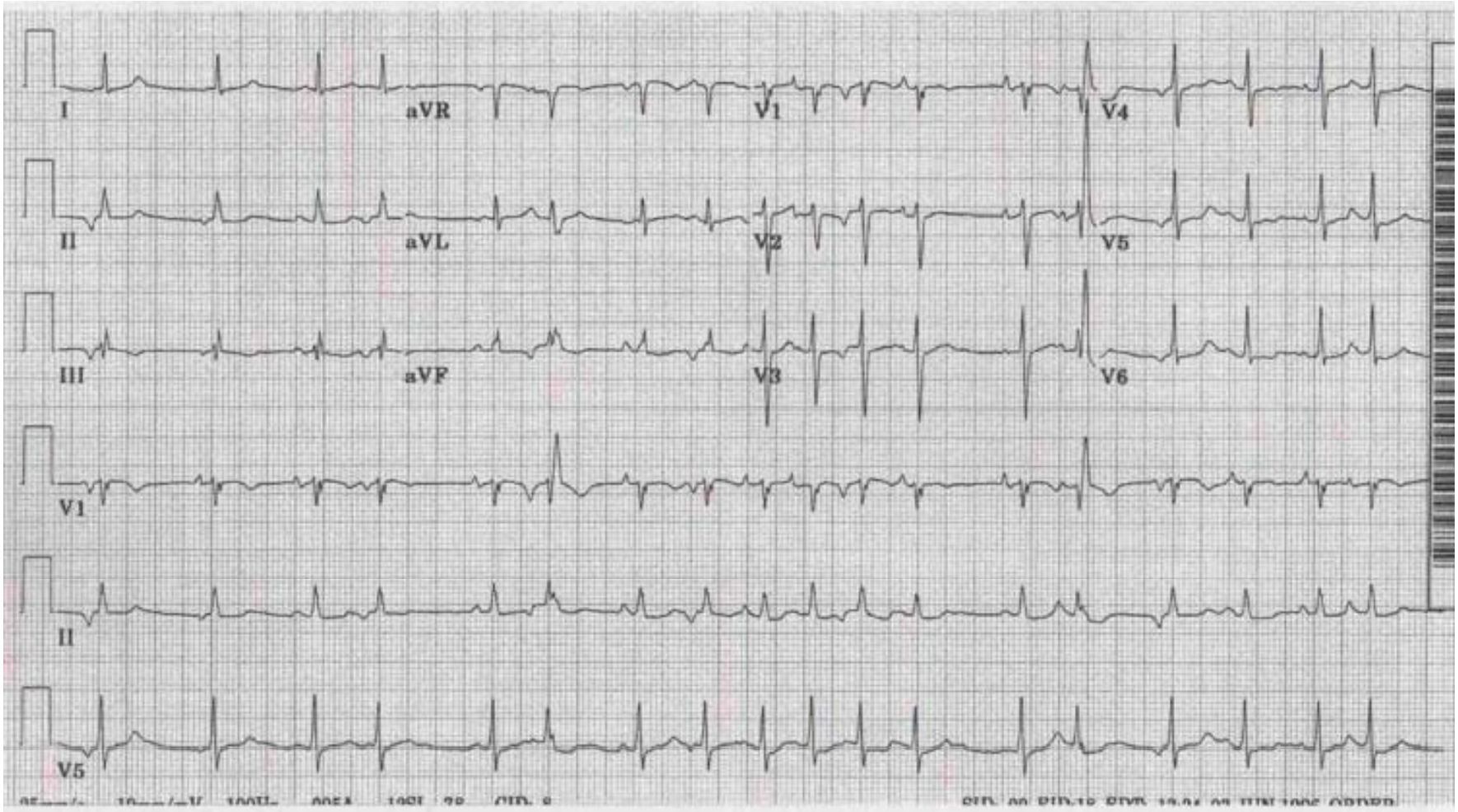

MAT

- At least three discernable p waves
- Rightward axis/right heart strain
- Tachycardia
- Treatment directed at underlying cause
- Dilated atria
- Irregularly irregular tachycardia

COPD Management

- Oxygen for hypoxemia
- Decrease work of breathing
- Maximize air exchange

EMS Management: JEMS Forum

- “Its short and sweet...O2 wont kill em befor you get to the ERD so give them all you got! SOB is SOB, COPD or not they are still SOB.”
- “Never withhold Oxygen from a hypoxic patient. Regardless if they have COPD.”
- “One has to assess the severity of dyspnea and treat accordingly, however one must remember that if you suppress their hypoxic drive its not only bag them. They will go on a vent and COPD pts have a historic difficulty in weaning. Also, the chance of and adverse event increases 6% for each hospital day. There is a long term consequences to this treatment”

COPD Management

What are some common strategies for the treatment of COPD ?

- *Bronchodilators*
- *Steroids*
- *Antibiotics*
- *Systemic beta agonists*

Eur Respir J, 1995, 8, 1894–1900
DOI: 10.1183/09031936.95.08111894
Printed in UK - all rights reserved

Copyright ©ERS Journals Ltd 1995
European Respiratory Journal
ISSN 0903 - 1936

Efficacy of noninvasive CPAP in COPD with acute respiratory failure

P. Goldberg[+*], H. Reissmann[**], F. Maltais[**], M. Ranieri[**], S.B. Gottfried[**#]

- 10 patients
- Critically ill with COPD, acute respiratory failure
- CPAP decreased inspiratory effort, dyspnea, and improved breathing pattern

- Patients in hypercapneic respiratory failure
- ICU population
- Those treated with NIV had shorter duration of treatment
- Fewer complications
- NO statistically significant differences in mortality

Intensive Care Med (2004) 30:1303–1310
DOI 10.1007/s00134-004-2320-7

ORIGINAL

Enzo Squadrone
Pamela Frigerio
Claudio Fogliati
Cesare Gregoretti
Giorgio Conti
Massimo Antonelli
Roberta Costa
Paola Baiardi
Paolo Navalesi

Noninvasive vs invasive ventilation in COPD patients with severe acute respiratory failure deemed to require ventilatory assistance

	NIV (n=64)	ETMV (n=64)	P Value
Nosocomial pneumonia, n(%)	8 (12)	12 (19)	.54
Pneumothorax, n (%)	0 (0)	2 (3)	.79
Hemoptysis	1 (2)	0 (0)	.93
Sepsis and MOF, n (%)	3 (5)	11 (17)	.18
Cardiovascular, n (%)	9 (14)	12 (19)	.66
GE Bleeding, n (%)	3 (5)	3 (5)	.93
Cerebrovascular, n (%)	2 (3)	0 (0)	.79
Renal failure, n (%)	1 (2)	2 (3)	.93

Acute respirator failure patients may deserve a trial of NIV

Non-invasive positive pressure ventilation for treatment of respiratory failure due to exacerbations of chronic obstructive pulmonary disease

Ram, Felix SF; Picot, Joanna; Lightowler, Josephine; Wedzicha, Jadwiga A

THE COCHRANE COLLABORATION®

Cochrane Collaboration 2009

- Decreased mortality
- Decreased need for ETI
- Decreased complications
- Decreased hospital LOS

Bottom line: It is probably safe to consider CPAP or non invasive ventilation early in the management of patients with respiratory failure from COPD

What about oxygen ?

Oh, crap! Here comes that damn non rebreather mask!

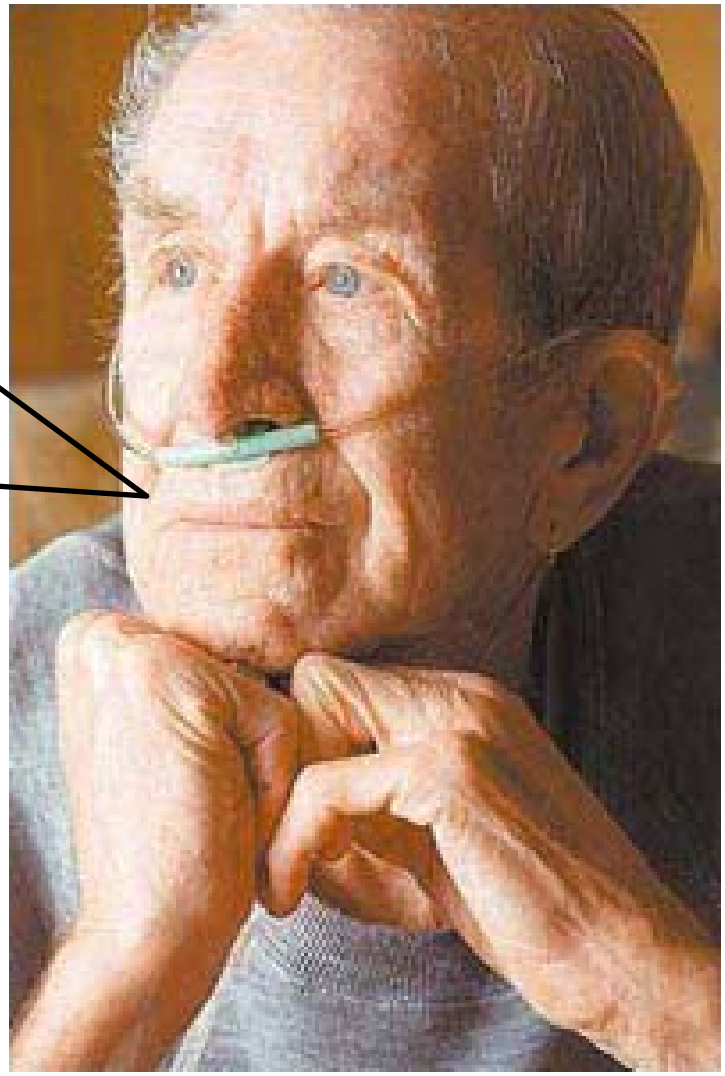

Initial oxygen management in patients with an exacerbation of chronic obstructive pulmonary disease

H.J. DURRINGTON, M. FLUBACHER, C.F. RAMSAY, L.S.G.E. HOWARD and B.D.W. HARRISON

From the Department of Respiratory Medicine, Norfolk and Norwich University Hospital, Norwich, Norfolk, UK

Received 25 January 2005 and in revised form 11 April 2005

- **EMS based, retrospective study in UK**
- **Transport times > 30 minutes**
- **Examined effects of HCO in patients with COPD**
- **Patients exposed to > 28% Fi02 had more complications, significantly worsened acidosis**

Effect of high flow oxygen on mortality in chronic obstructive pulmonary disease patients in prehospital setting: randomised controlled trial.
Austin MA, Wills KE, Blizzard L, Walters EH, Wood-Baker R.

- 405 patients
- 214 with confirmed COPD diagnosis
- 226 treated with high flow oxygen
- Mortality higher (9% in HCO group vs 4% in titrated group)
- Less respiratory acidosis in titrated oxygen group

COPD Treatment Summary

- Oxygen is a drug, treat it as such!
- Consider NIV early in respiratory failure
- History is key to formulating field impression

And What About Pulmonary Edema?

CHF: In the History

- Provider suspicion
- Exertional dyspnea
- Orthopnea
- Dyspnea at rest
- Paroxysmal nocturnal dyspnea

CHF: Orthopnea

- Occurs rapidly
- Within 1-2 minutes
- Complicated by low vital capacity
- Ascites can worsen orthopnea
- Cough may be an “orthopnea” equivalent

CHF:History

- Fatigue
- Weakness
- Chest pain/palpitations
- Nocturia and oliguria
- Cerebral symptoms

Assessment of CHF

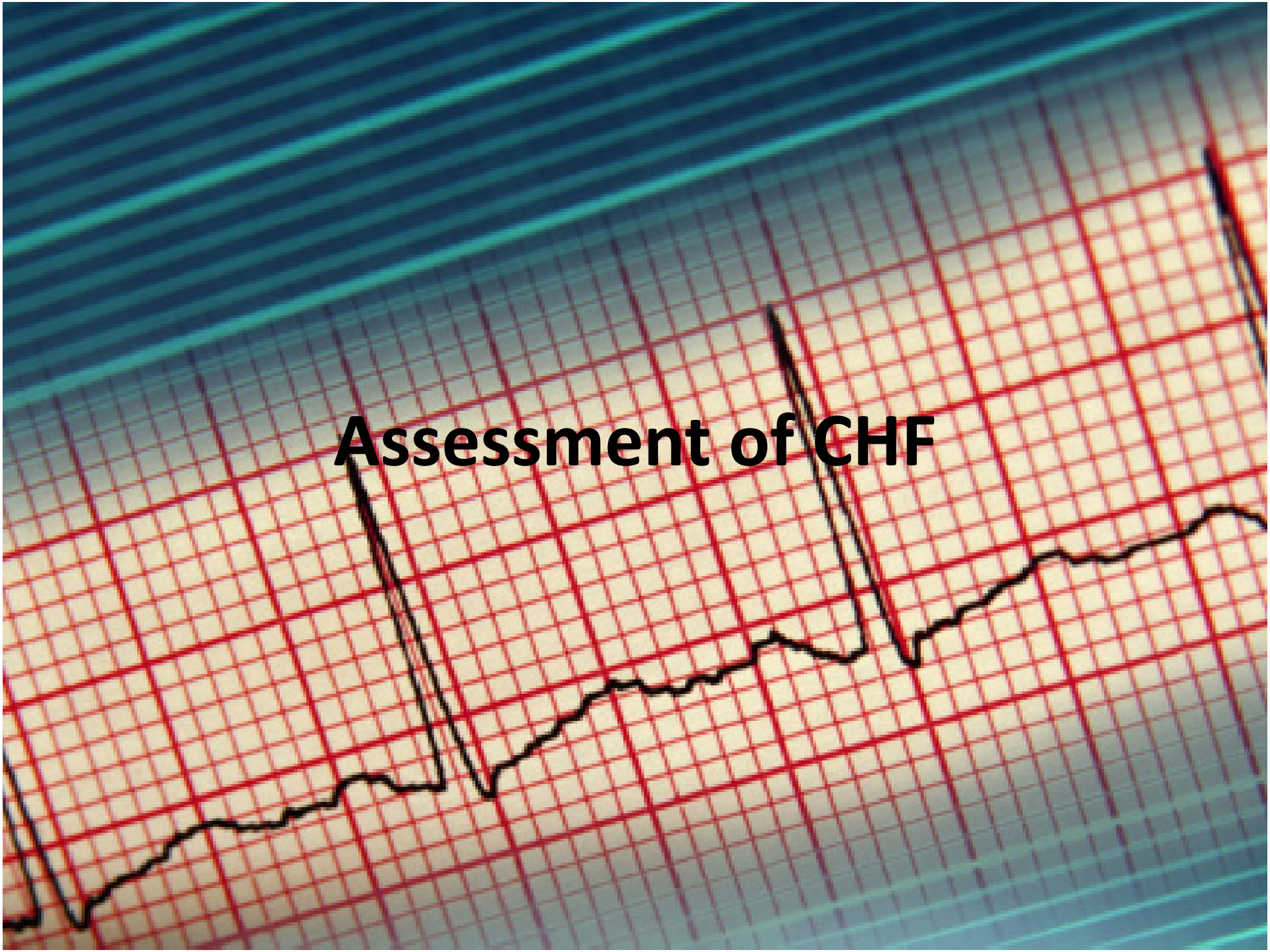

What About an S3?

CARDIOLOGY/ORIGINAL RESEARCH

S3 Detection as a Diagnostic and Prognostic Aid in Emergency Department Patients With Acute Dyspnea

- ***Did NOT improve diagnostic accuracy***
- ***Did NOT change practice***

CHF: Assessment

- Ascites
- Tachycardia
- Bi-basilar rales

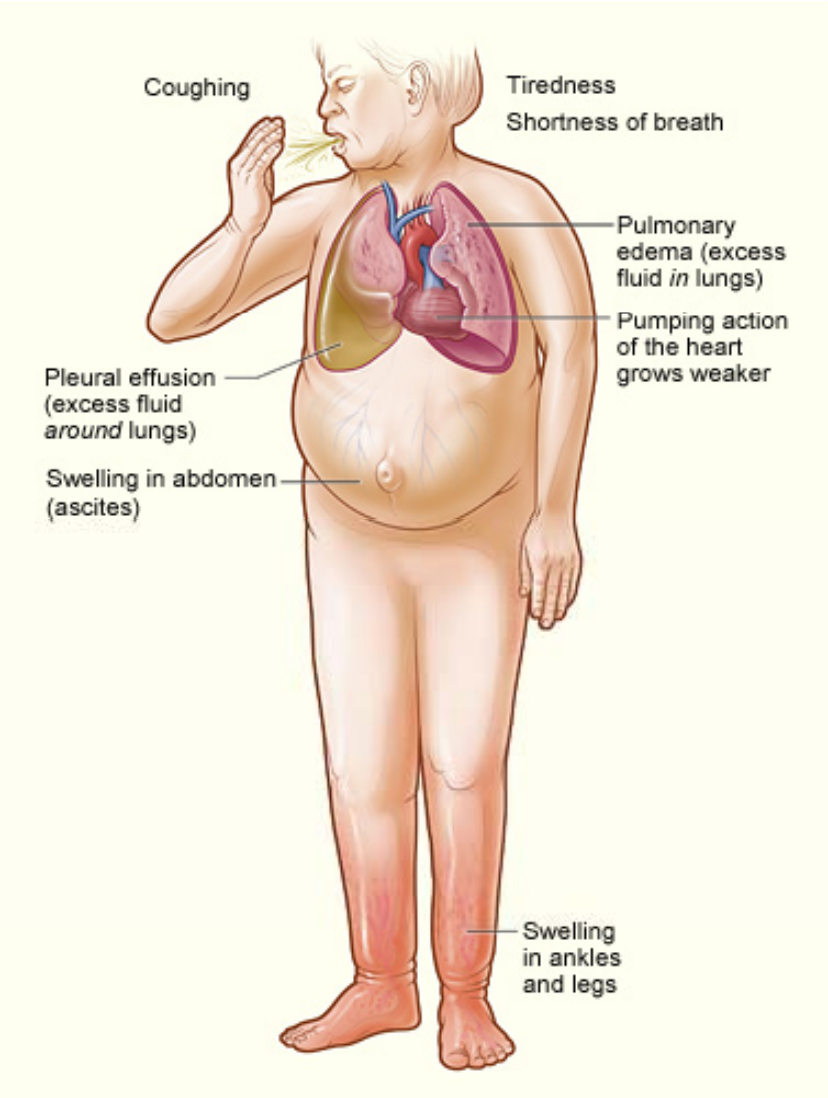

CHF: JVD

- Measurement is subjective and difficult
- Straight column of blood in contact with RA
- Measure with patient 45 degrees above horizontal
- >3cm from sternal angle = elevated RAP

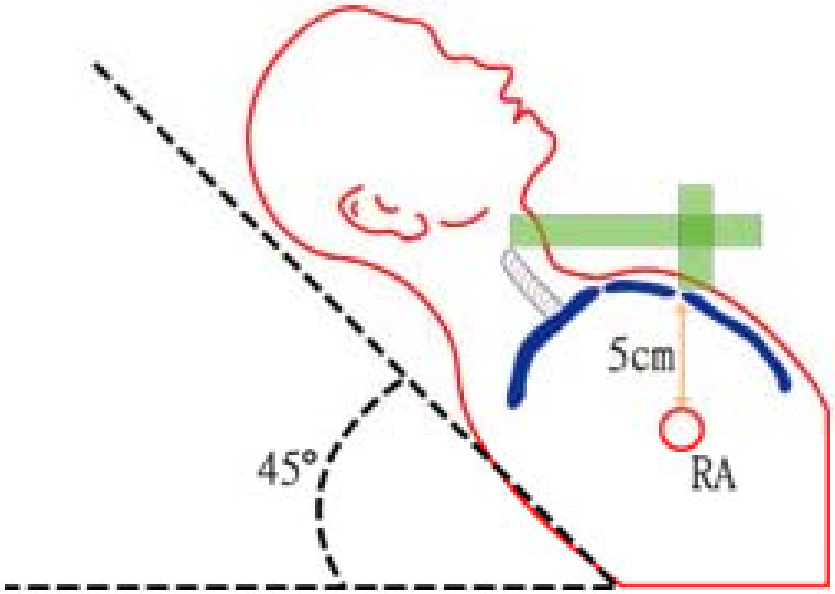

CHF: Edema?

- Present in right / left sided
- Presence or absence not specific
- Presence may suggest diagnosis
- Take edema in CONTEXT with rest of exam
- ***A significant percentage of patients in CHF may be fluid depleted!***

CHF: EKG Findings

- Deep Q waves
- Bundle branch block
- Tachycardia
- Poor R wave progression
- STEMI

CHF: EKG Findings

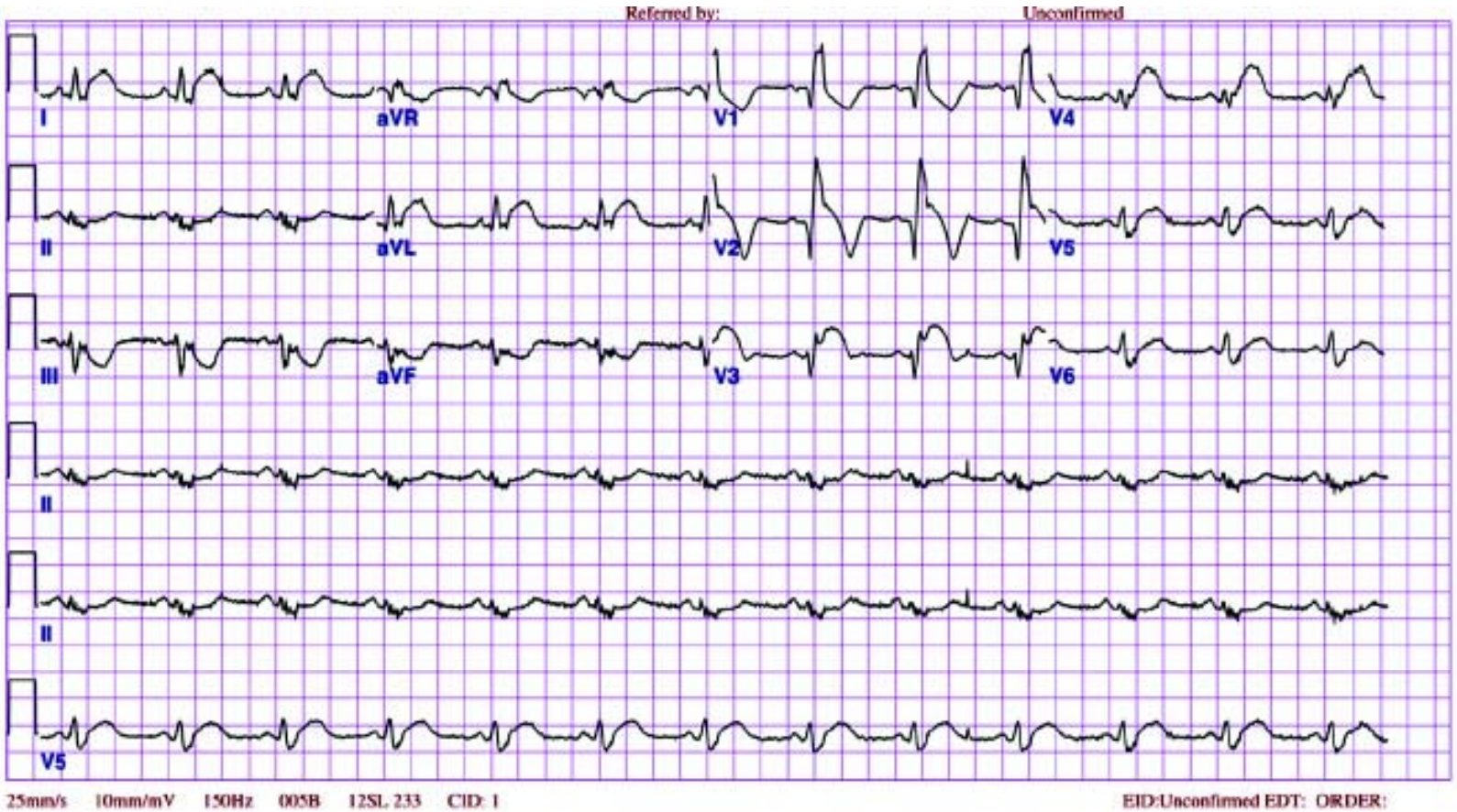

Figure 33. Twelve-lead ECG in a patient with anterior STEMI complicated by right bundle-branch block (RBBB) and left anterior fascicular block. Note the convex upward ST-elevation in V_2-V_3 consistent with anterior STEMI RBBB; the anticipated r-wave of the conventional rsR' pattern of RBBB has been replaced by a Q wave in V_1-V_2 as a result of anterior STEMI. The initial 80-ms forces of the QRS in the frontal plane are deviated to the left as a result of left anterior fascicular block. ECG = electrocardiogram; STEMI = ST-elevation myocardial infarction.

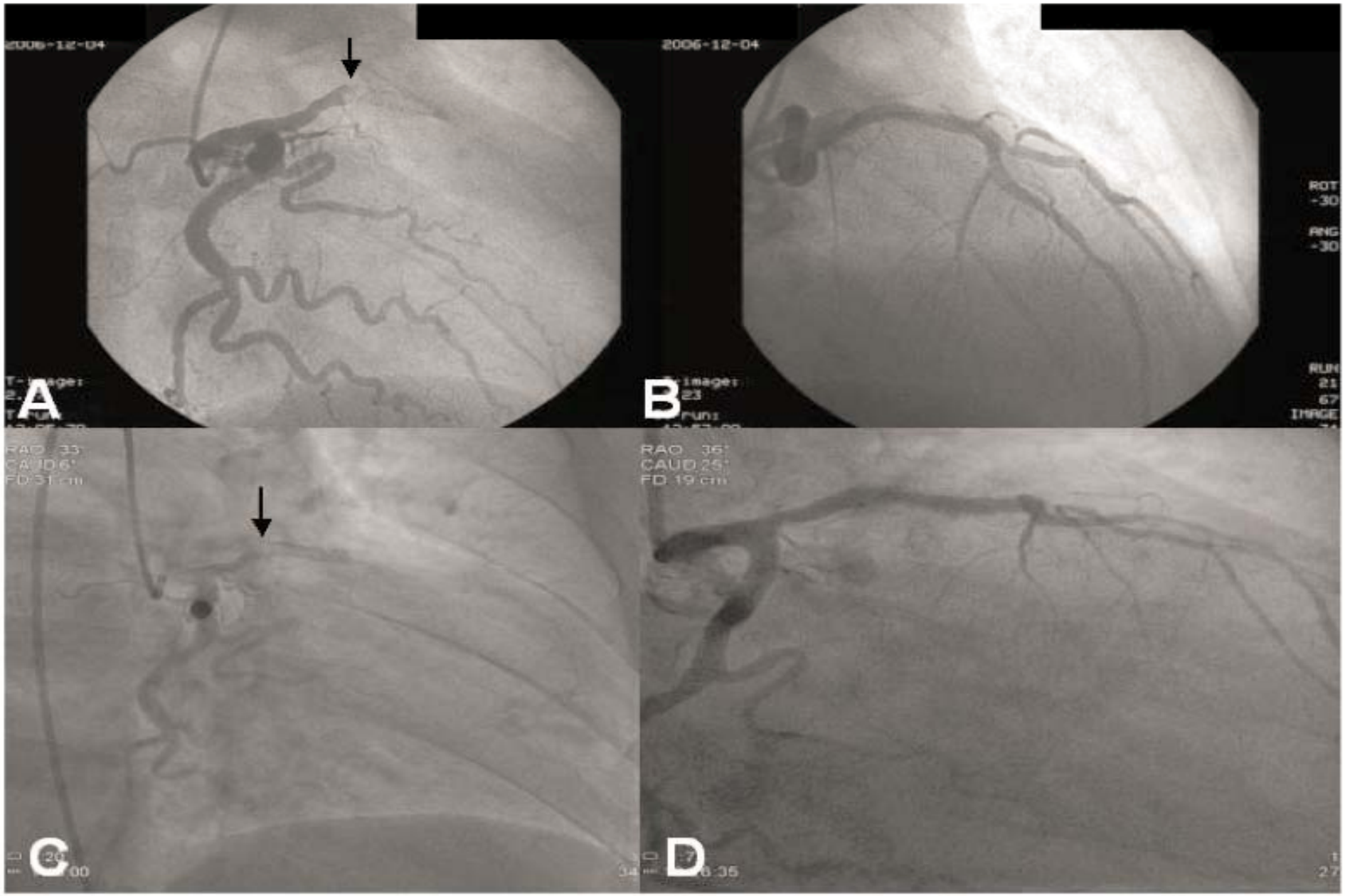

Figure 2. (A) *coronary angiogram performed 14 months after subacute stent thrombosis revealed a thrombotic in-stent total occlusion of the left anterior descending (LAD) coronary artery (arrow).* **(B)** *After balloon angioplasty and implantation of a 3.5 x 24 mm TAXUS™ stent, successful reperfusion was achieved.* **(C)** *Coronary angiogram performed 1,166 days (50 months) after first late stent thrombosis revealed a thrombotic in-stent total occlusion of the LAD (arrow).* **(D)** *After balloon angioplasty and implantation of a 3.5 x 20 mm Promus™ stent, successful reperfusion was achieved.*

Why Accurate Assessment is Important in CHF

Jaronik (2006) Prehospital Emergency Care

144 patients
Diagnosis of sepsis, dehydration, or pneumonia occurred in 17% given furosemide

CHF Interventions

- Early CPAP decreases mortality
- Early, aggressive NTG decreases mortality
- Appropriate treatment decreases ICU LOS
- Appropriate treatment decreases ETI

The Sickest of the Sick

70 yo male requests EMS for shortness of breath. Upon arrival, patient is alert but somnolent. Patient speaking in 3-4 word sentences. Patient denies chest pain. Endorses orthopnea, coughing, fatigue. BP: 86/50, P: 112, R: 25. Sp02: 94% on room air.

The Sickest of the Sick

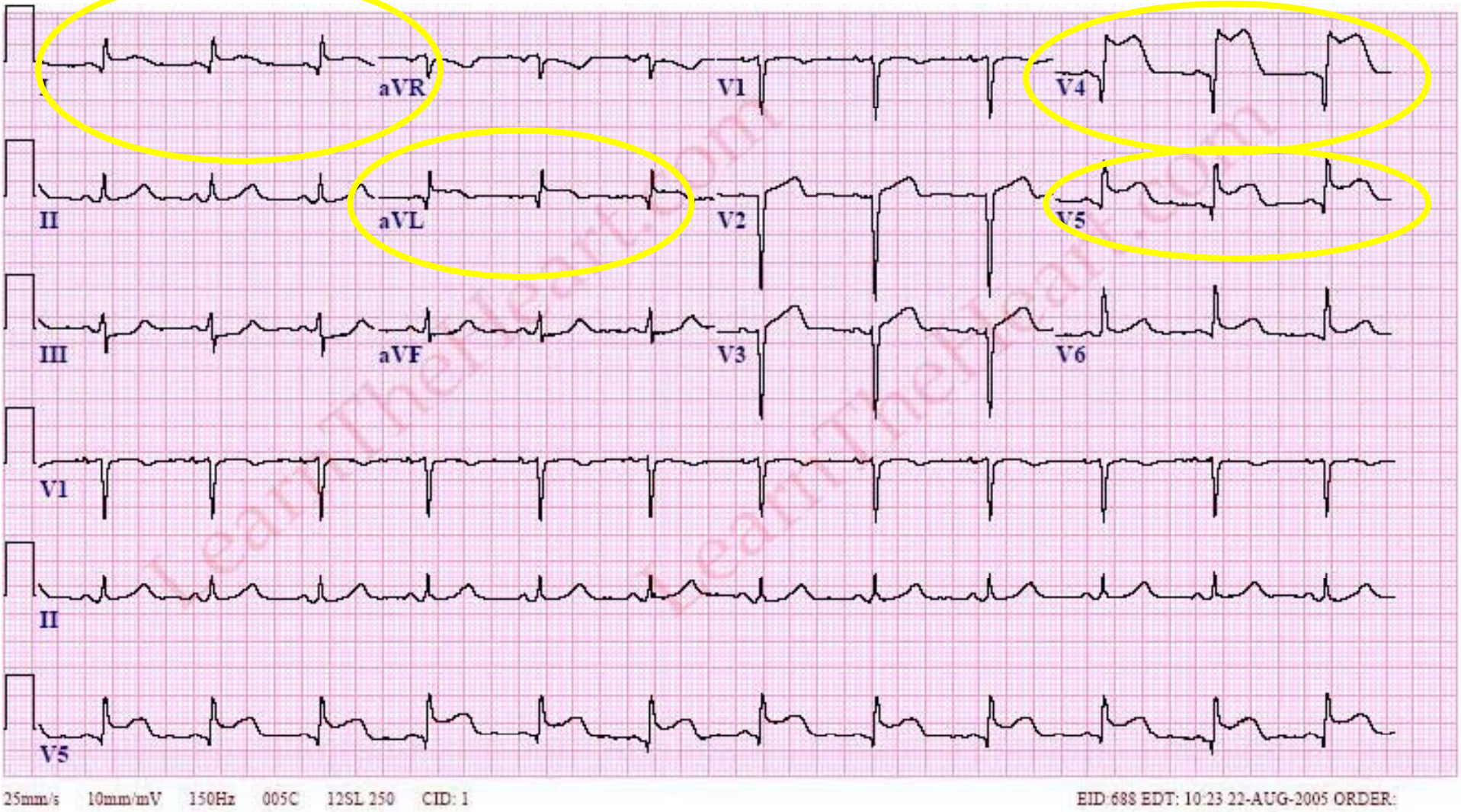

The Sickest of the Sick

- What is your ECG diagnosis?
- What are two deadly complications you must anticipate ?
- What are your next interventions ?

CHF Assessment

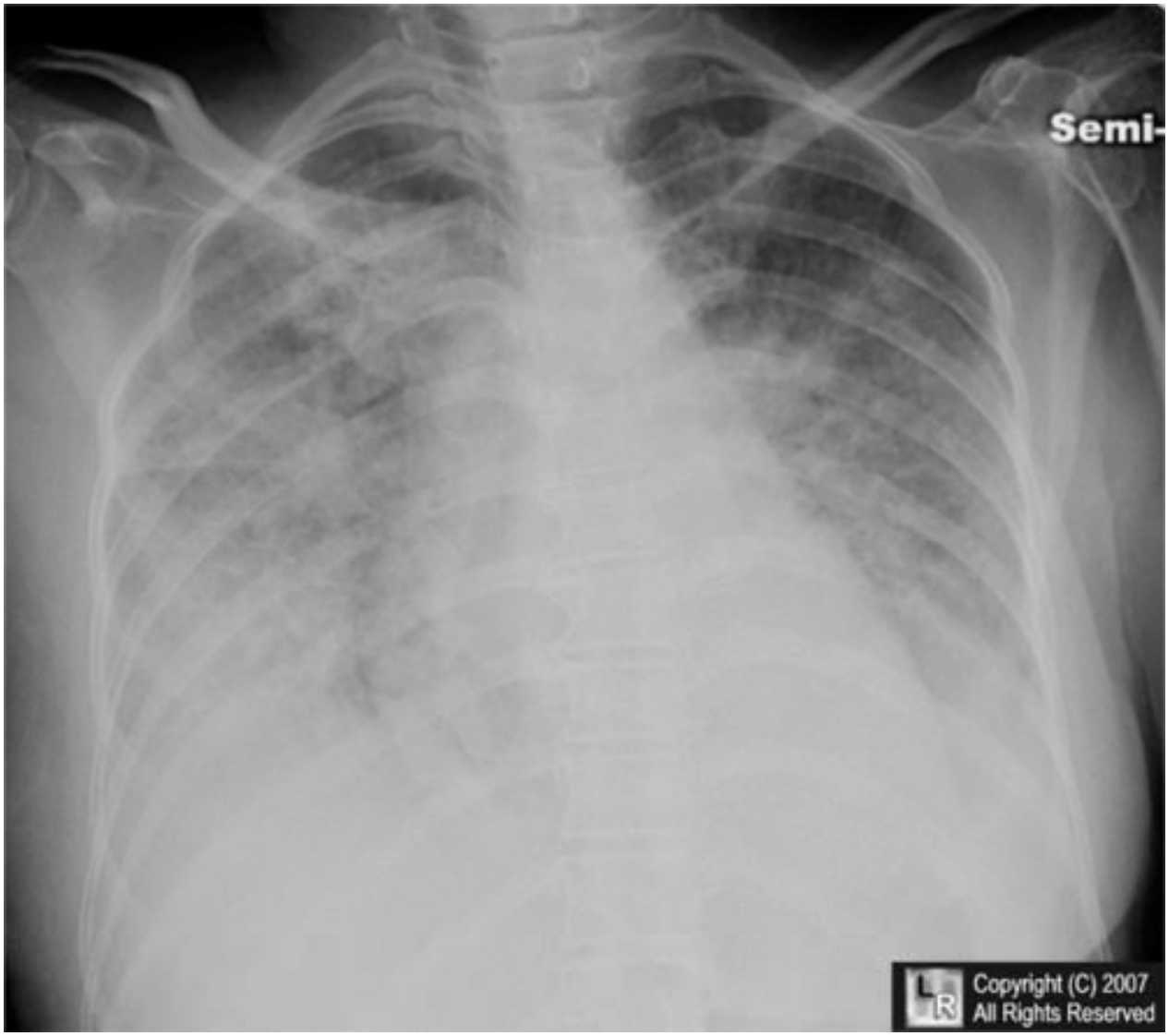

CHF Management

CHF Management

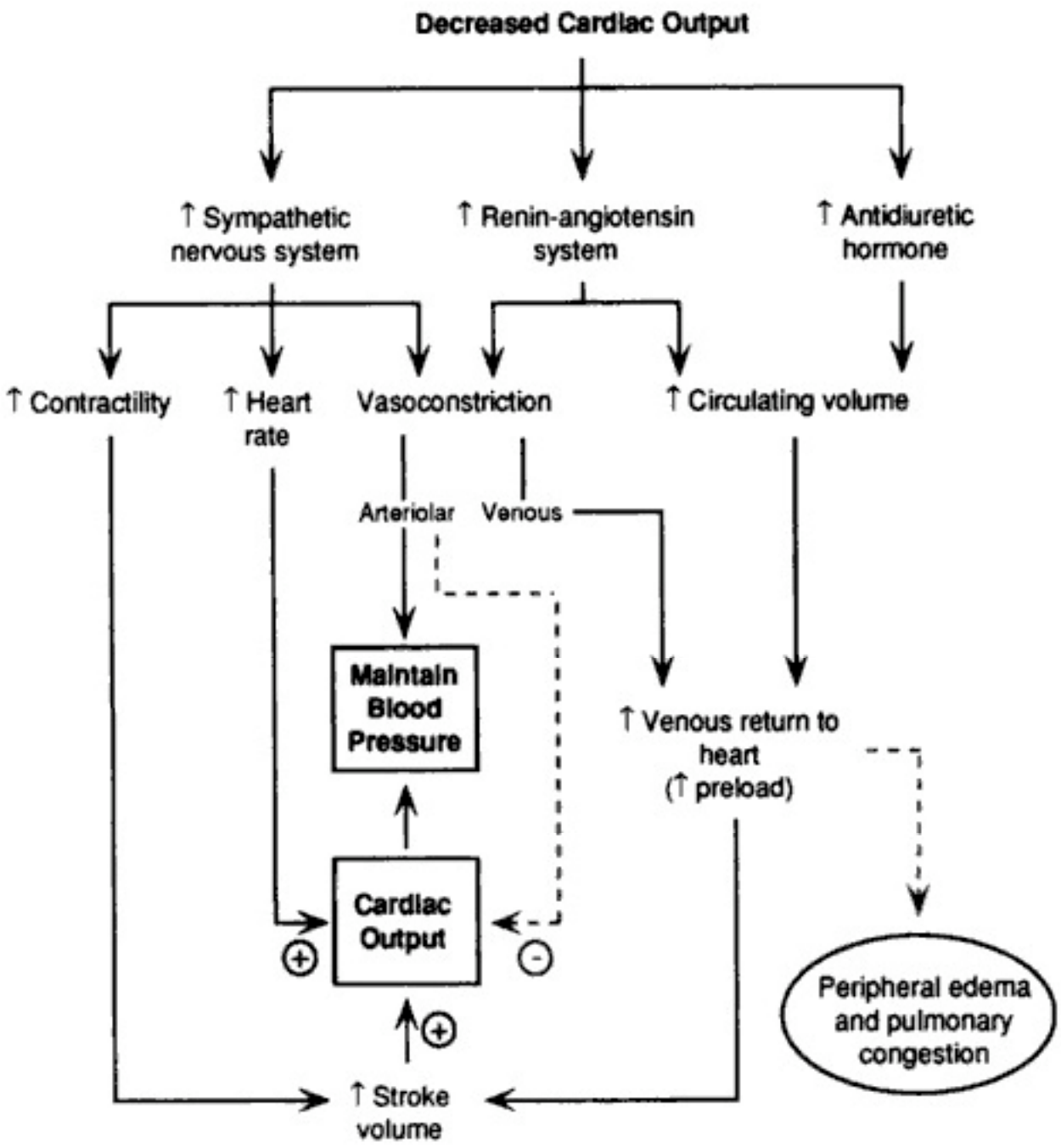
Decreased Cardiac Output
↑ Sympathetic nervous system
↑ Renin-angiotensin system
↑ Antidiuretic hormone
↑ Contractility
↑ Heart rate
Vasoconstriction
↑ Circulating volume
Arteriolar
Venous
Maintain Blood Pressure
↑ Venous return to heart (↑ preload)
Cardiac Output
Peripheral edema and pulmonary congestion
↑ Stroke volume

Signs of Sickness in CHF



NYHA Classes

- **Class I:** No physical activity limitations
- **Class II:** Ordinary physical activity results in dyspnea
- **Class III:** Marked limitation in activity
- **Class IV:** Symptoms present at rest

Sickest of the Sick

- Low “EF” results from prior massive MI
- Severe limitation in symptoms
- Patients at risk for dysrhythmia, complications
- Resynchronization therapy
- LVADs
- Transplant

Normal Ejection Fraction



Low Ejection Fraction



Case Study Summary

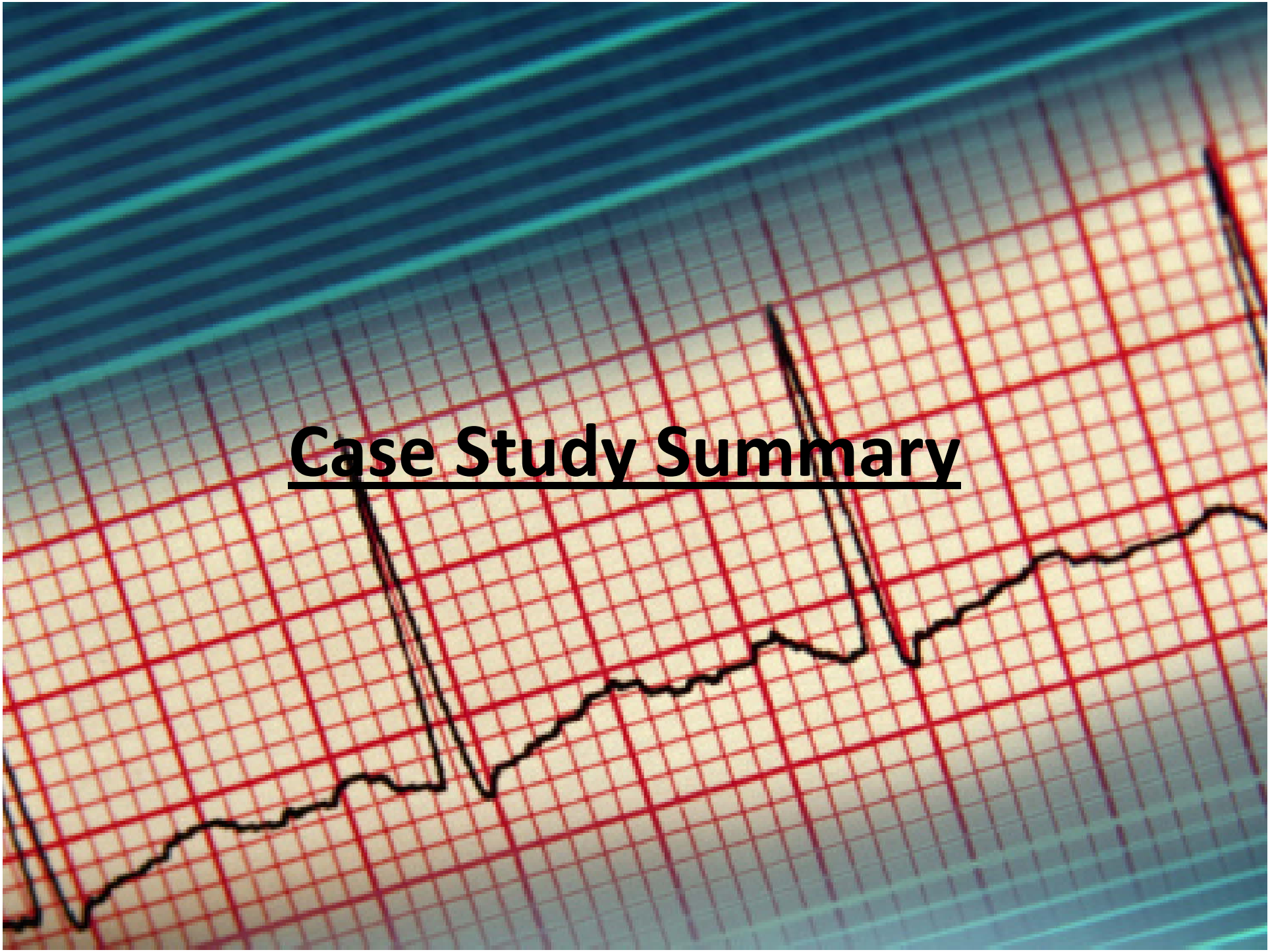

Case 1

72 yo female presents with three days of fatigue and cough. Patient states she “has a cold.” Patient reports exertional dyspnea, fatigue, and denies chest pain. She appears pale.

BP:	189/80
P:	116
R:	26
Sp02:	92-95% RA

Case 1

The patient is awake, alert, and oriented. Lung sounds reveal bilateral rales. Mild abdominal retractions Bilateral pedal edema is present.

What is your impression ?
What are your treatment priorities ?

Case 2

A 72 yo male calls 911 for coughing and shortness of breath. He has had upper respiratory symptoms for the past 5 days. He reports exertional dyspnea. The patient denies orthopnea and chest pain.

BP:	189/100
P:	116/irregular
R:	26
Sp02:	92% on RA

Case 2

The patient is awake, alert, and oriented. Wheezing is scattered and appreciated bilaterally. There is supraclavicular accessory muscle use. Lung sounds are otherwise diminished.

What is your impression ?

What are your treatment priorities ?

Case 3

A 65 yo male presents in extremis. He speaks in one word sentences and reports a sudden onset in shortness of breath. The patient is diaphoretic and extremely agitated. The patient's wife states that he had been more fatigued during the past 48 hours. The patient has a history of CAD, HTN, and DM.

BP:	210/100
P:	130
R:	32
Sp02:	89%

Case 3

Further history is unobtainable. The patient is difficult to calm. Audible rales are present. Abdominal and intercostal retractions are seen. Air movement is poor.

What is your impression ?

What are your treatment priorities ?

Thank You!

blawn001@umaryland.edu