

Neonatal Resuscitation for EMS Providers

Alix Paget-Brown, MD FAAP

Associate Professor, Division of Neonatology
Associate Medical Director, UVA Medical
Transport Network,
University of Virginia
Charlottesville, VA



Goals

1. Identify the first steps of neonatal resuscitation
2. Identify aspects of field management which complicate neonatal resuscitation
3. Identify airway differences between the neonate and other age groups
4. Describe methods of basic neonatal airway management
5. Identify several neonatal airway abnormalities, airway emergencies and respiratory diseases
6. Describe management techniques for neonatal airway emergencies and respiratory diseases

Outline

- The Basics of Neonatal Resuscitation
- Field Considerations
- The Neonatal Airway
- Basic Neonatal Airway Management
- Airway Abnormalities
- Prehospital Management of Airway Emergencies and Respiratory Diseases

Outline

- *The Basics of Neonatal Resuscitation*
- Field Considerations
- The Neonatal Airway
- Basic Neonatal Airway Management
- Airway Abnormalities
- Prehospital Management of Airway Emergencies and Respiratory Diseases

Basic Neonatal Resuscitation

- Clamp cord
- Goals:
 - **Assess**
 - **Airway Breathing Circulation**
 - **Address findings**
 - **Warm, dry, stimulate**
 - Do NOT place infant on Mom's chest if it is not vigorous

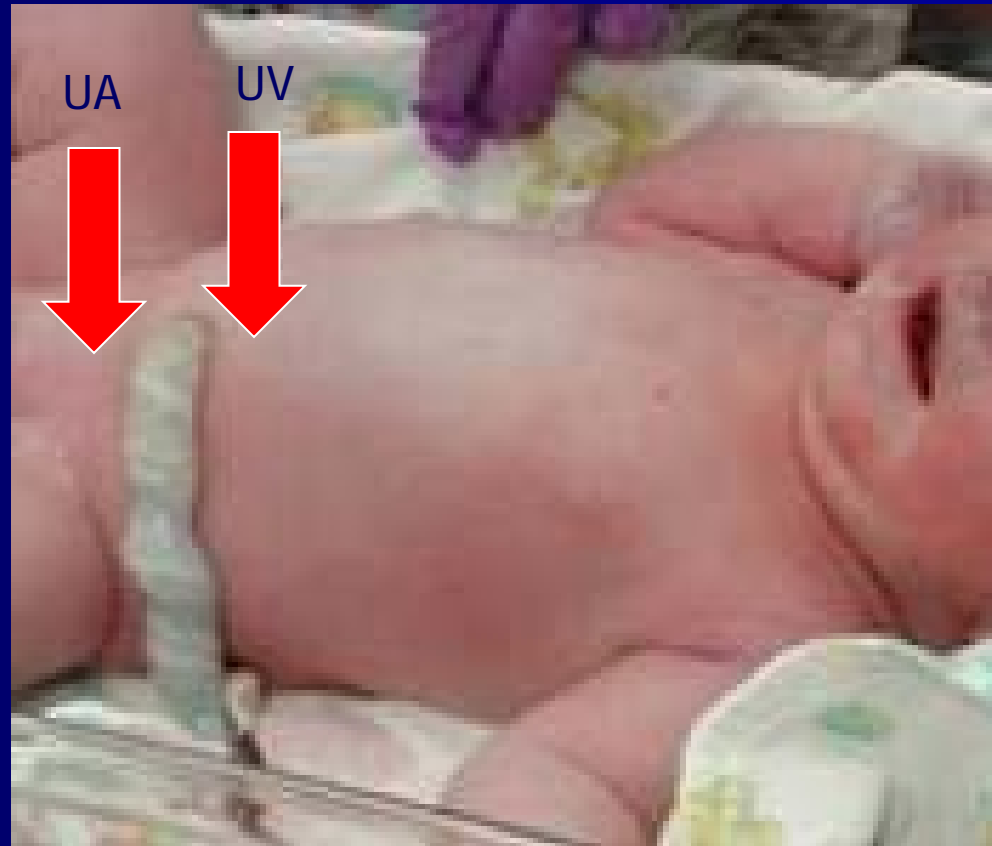Cord Clamping and Care

- ACOG recommendation of 30-60 seconds of delayed cord clamping
 - Baby level with mom
- Inappropriate position during cord clamping:
 - Hypovolemia
 - Delayed clamping, baby in high position
 - Polycythemia
 - Delayed clamping, baby held below mother

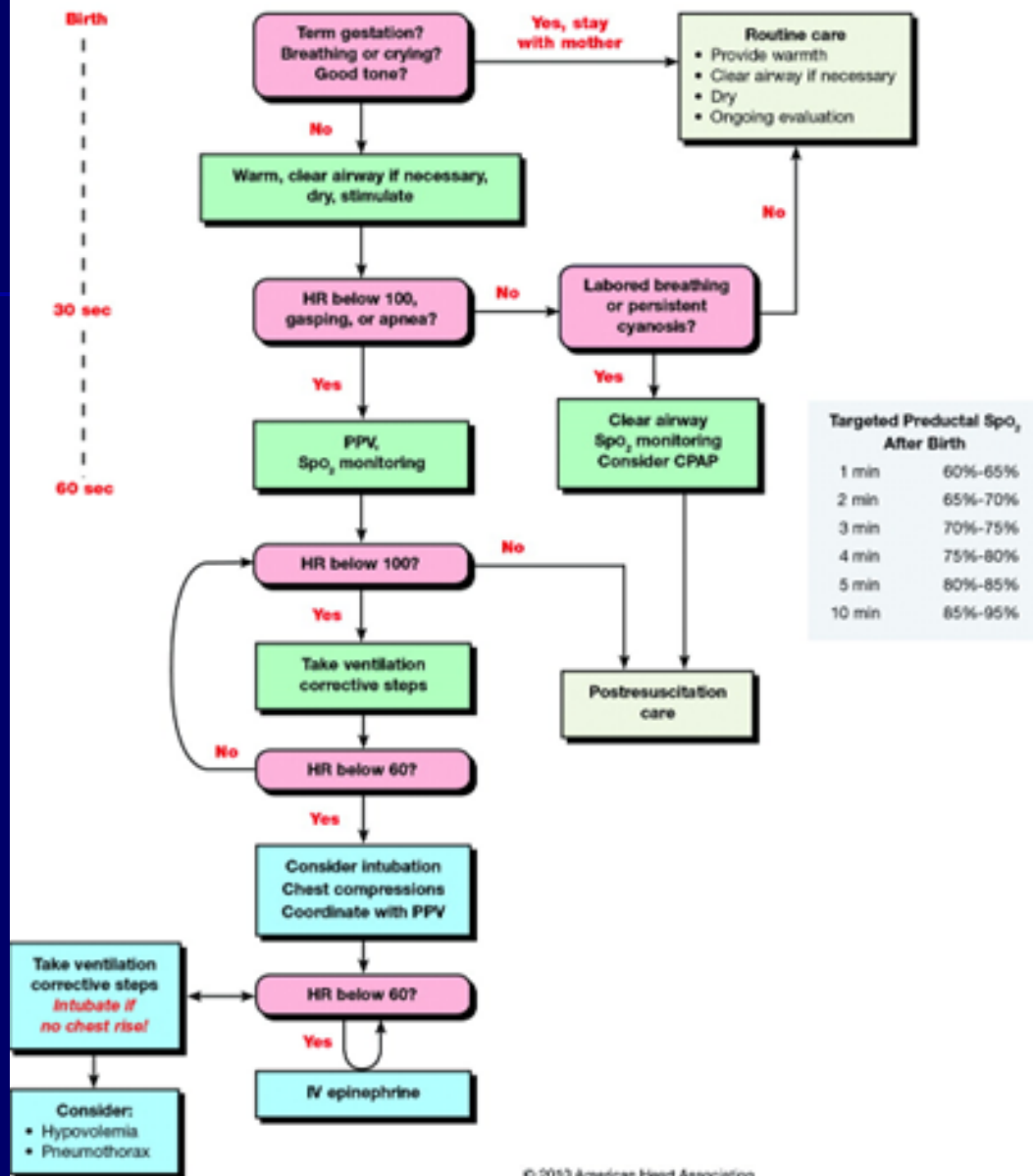
Cord Accidents

- Tearing (avulsions) of the umbilical cord
 - Slicing through cord by using dental floss
 - Cord or clamp catches and tears
 - Tearing of cord after delivery
- IMMEDIATELY
 - Pinch cord
 - Apply **STRONG** pressure above and below umbilicus

Pressure Application



Newborn Resuscitation



**Targeted Preductal SpO₂
After Birth**

1 min	60%-65%
2 min	65%-70%
3 min	70%-75%
4 min	75%-80%
5 min	80%-85%
10 min	85%-95%

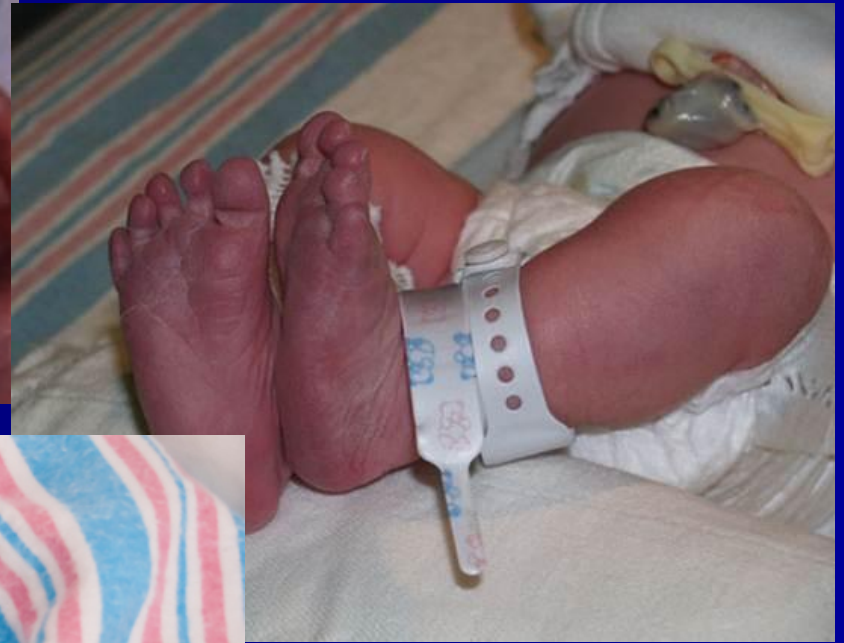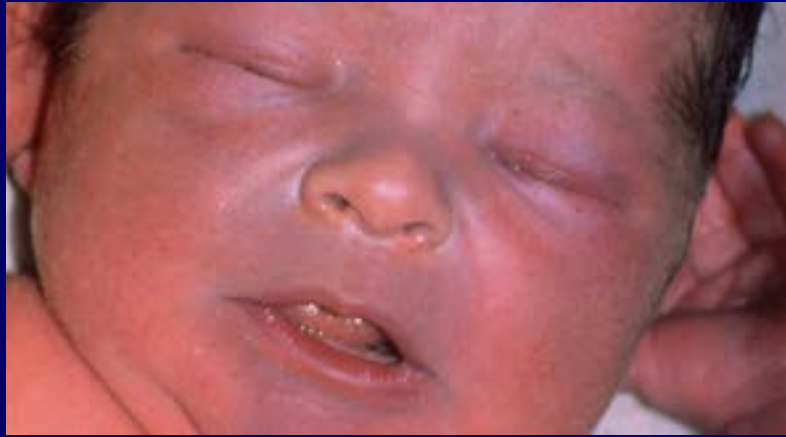Assessment (1)

- Term Gestation?
 - Peeling/cracking skin
 - Vernix caseosum
 - Scant lanugo
 - Well defined palmar/plantar creases
 - Well defined genitalia

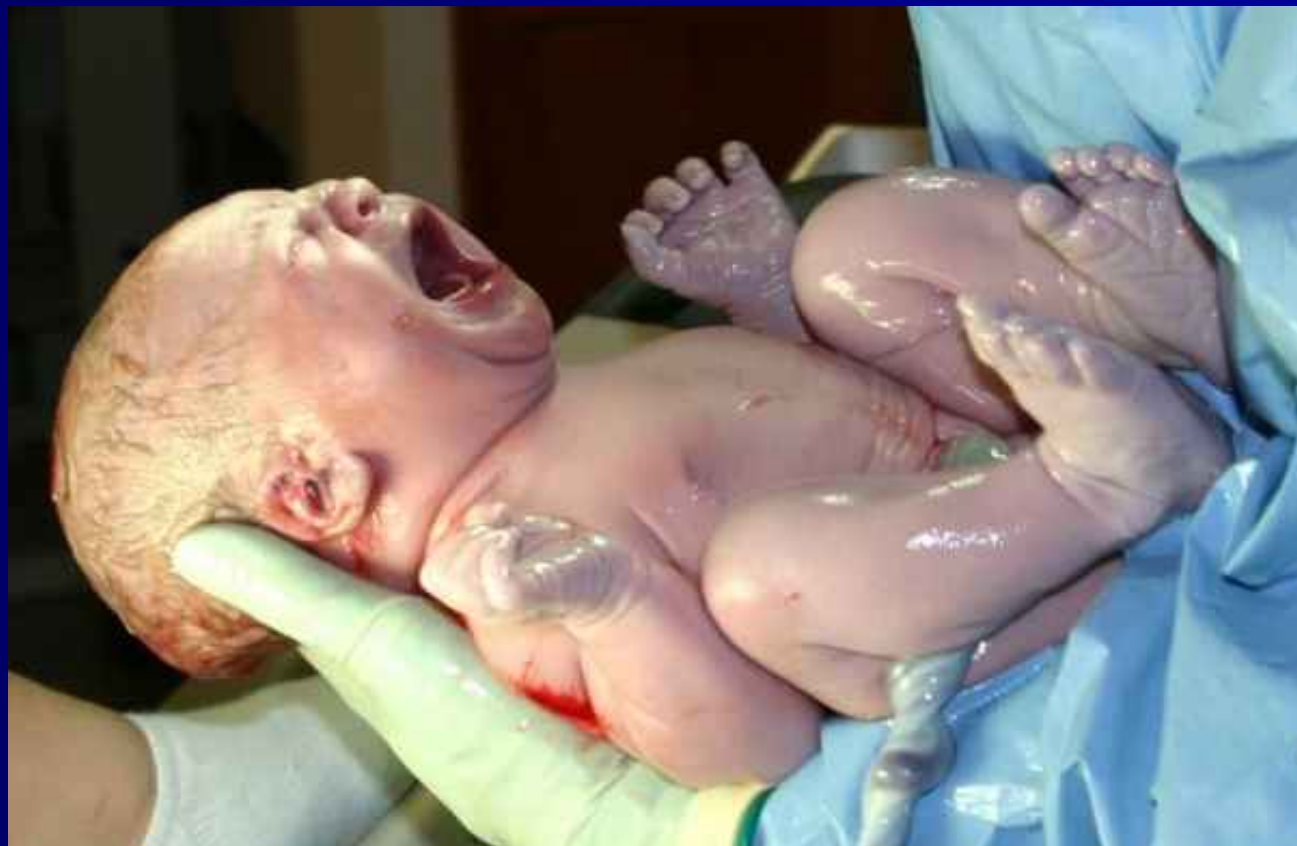Assessment (2)

- Breathing/Crying
- Color
 - Acrocyanosis is normal
 - Color should be pink centrally within 15 minutes of birth
 - Mottling should not be present
- Muscle tone

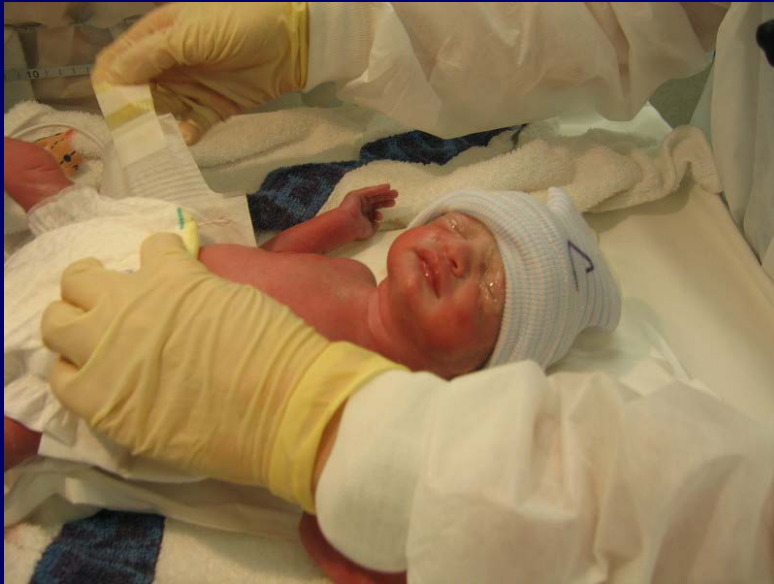Color???



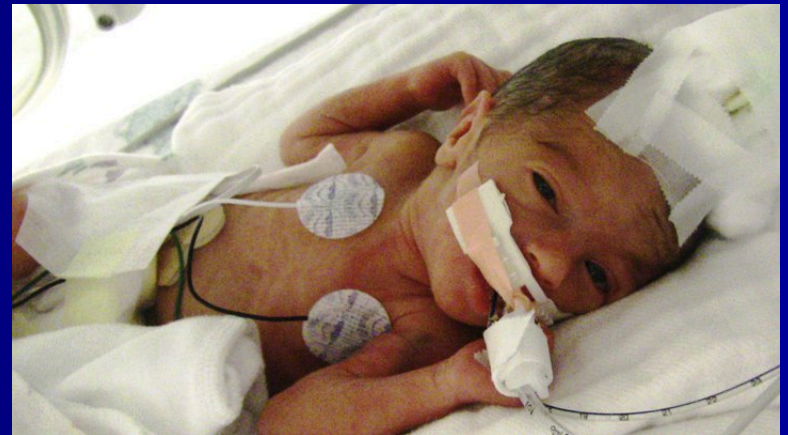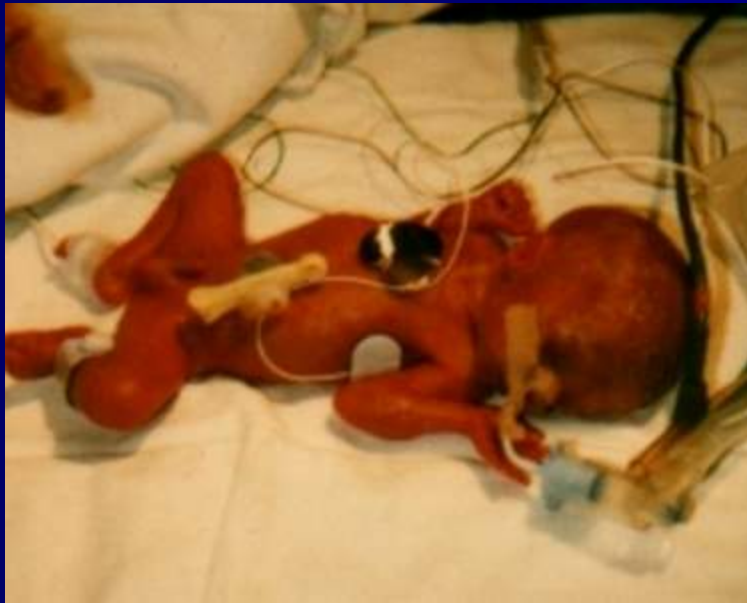Full Term Newborn



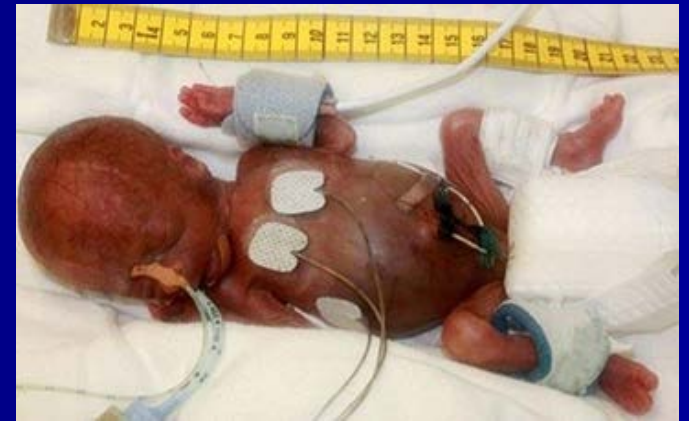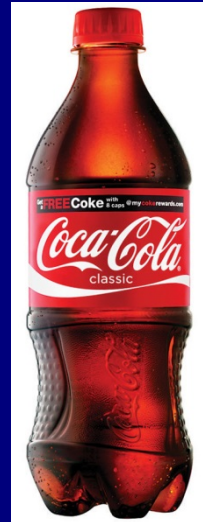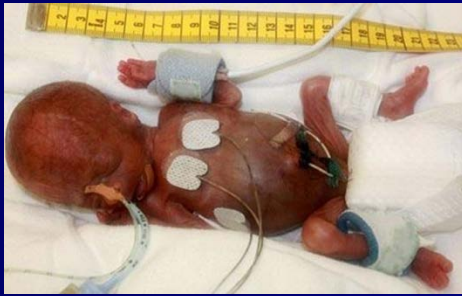32 week gestation



25-27 week infant



Size comparisons



Vital Signs

- Breathing
 - Present?
 - Regular?
 - Labored? (grunting, intercostal retractions)

Risks Specific to Premature Deliveries

- Immature lungs
 - Respiratory Distress Syndrome
 - Surfactant deficiency
 - Signs
 - Grunting
 - Retractions
 - Nasal flaring
 - Supplemental oxygen requirement
 - Difficulty ventilating
 - Complications
 - Pneumothorax
 - Chronic lung disease of prematurity (long term)

Retractions

<http://www.youtube.com/watch?v=J2R8MOoQtd8>

Grunting

[http://www.youtube.com/
watch?v=NBA9iigiDgk](http://www.youtube.com/watch?v=NBA9iigiDgk)

Stridor

<http://www.youtube.com/watch?v=QkaX83H31QY>

Vital Signs

■ Heart rate

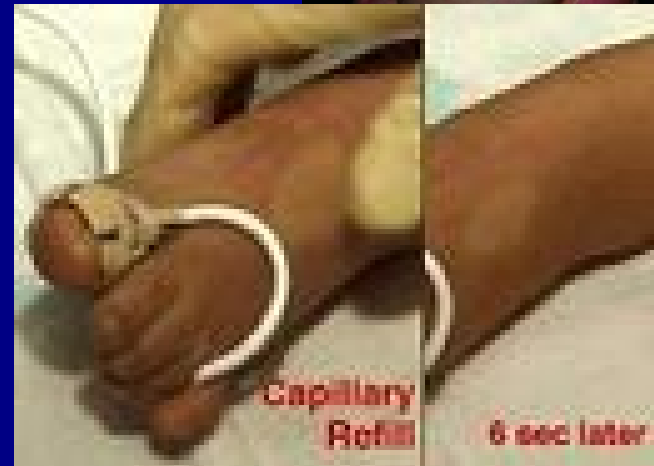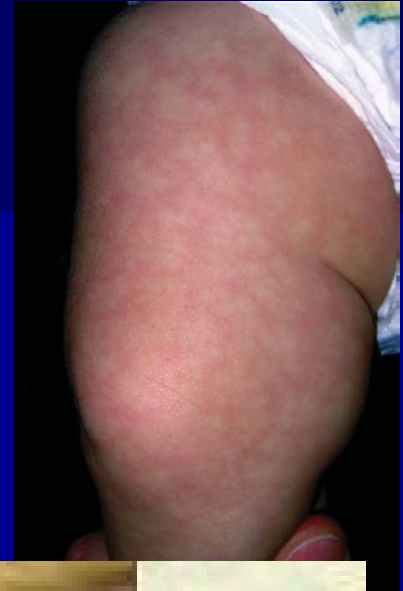- >100 – normal
- 60-100 – intervene with oxygen/PPV if poor breathing
- <60 – Supplemental oxygen/PPV and chest compressions until heart rate >60

■ Perfusion

- Color, mottled, capillary refill time

Poor Perfusion

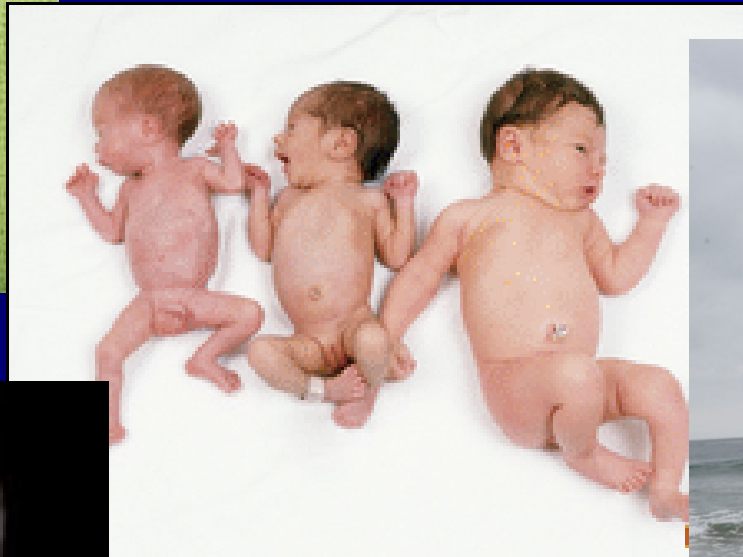- Mottled appearance (above)
- Delayed capillary refill time (below)
- Indications of poor perfusion
- Centralizing of perfusion



Risks Specific to Premature Deliveries

- Skin immaturity
 - ↑ Insensible water losses
 - ↑ Heat loss
 - ↑ Bruising
 - ↑ Sloughing
- Brain and vascular immaturity
 - Brain bleeds
 - Blood pressure instability

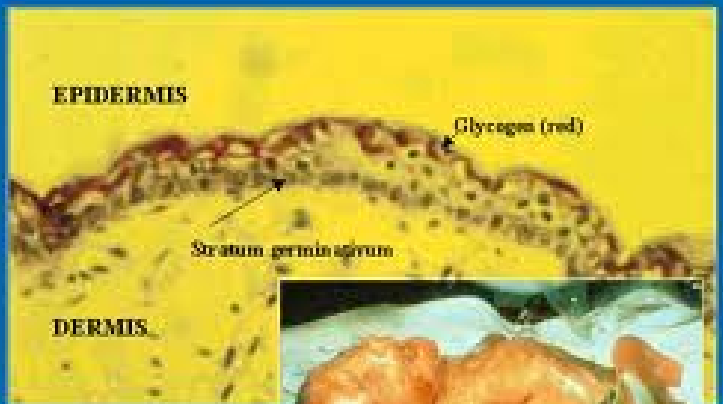
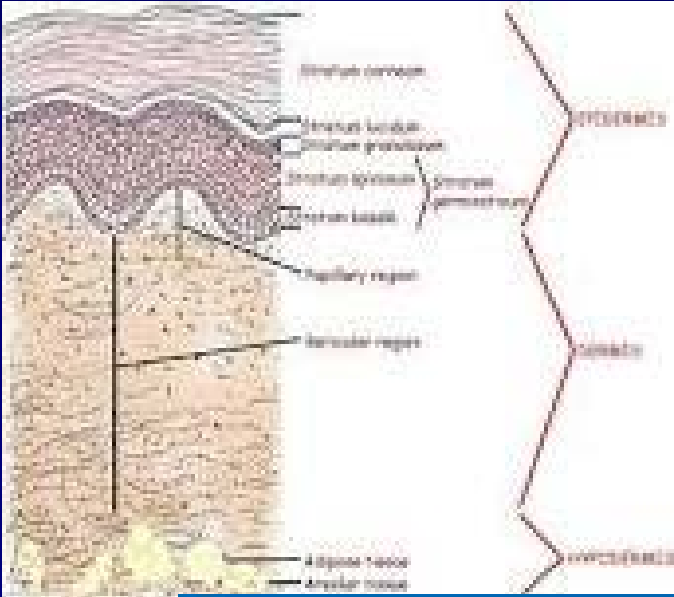
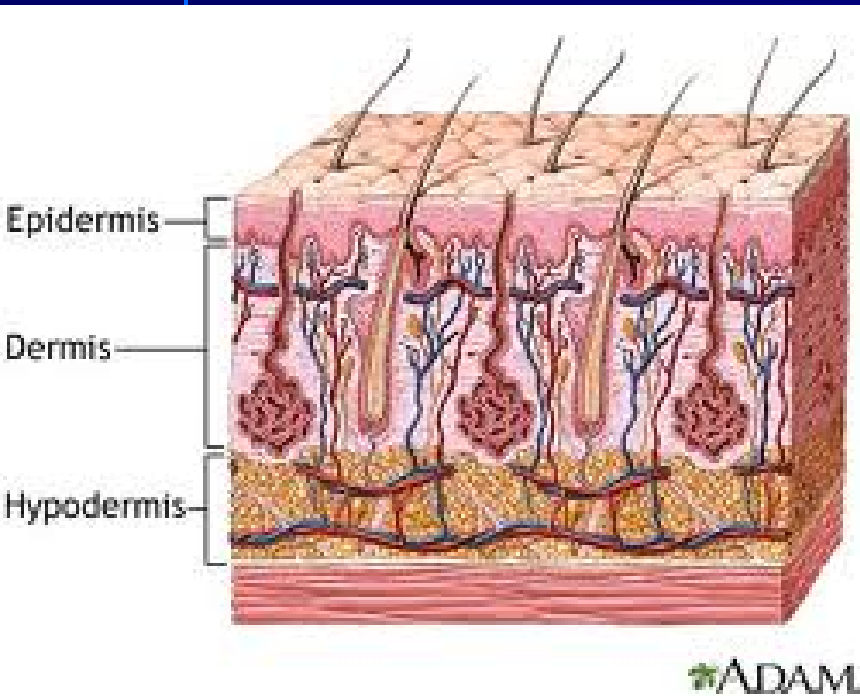
Surface Area



Surface Area

- Small weight, but large surface area
 - Proportionally larger head
 - Larger torso
- Increased effect of temperature
- Risk of hypothermia
- Insensible water loss

Skin...



PRETERM INFANT

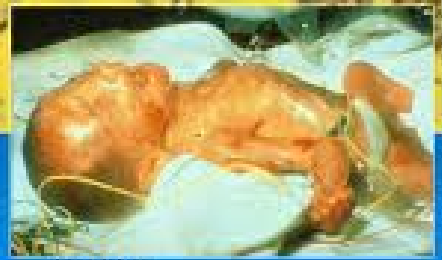
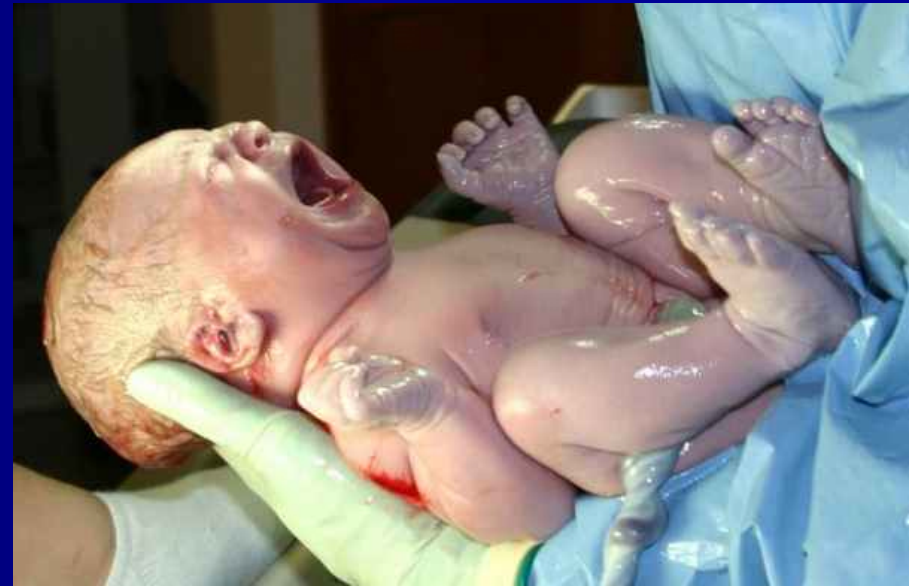
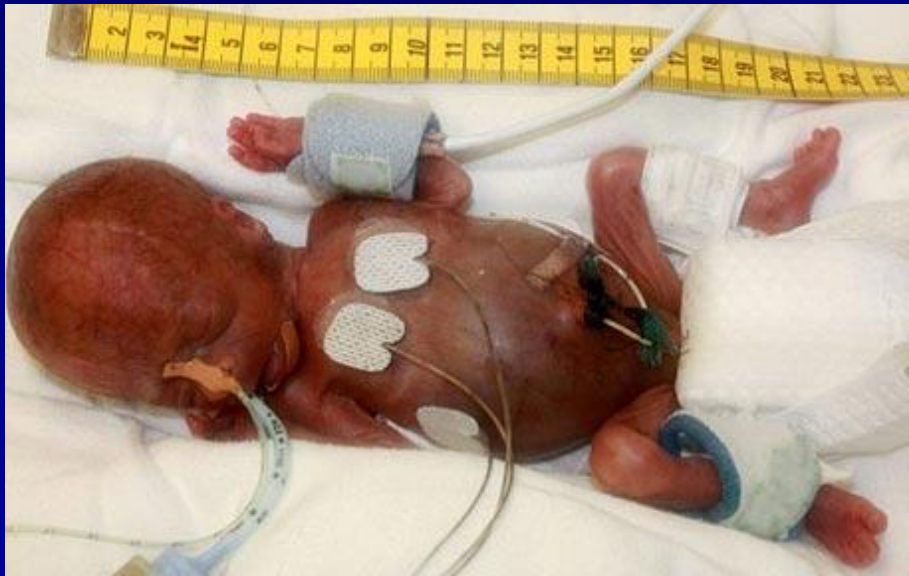Figure 5.7

Skin

- Largest immune organ in the body
- Noticeably immature/thin in premature infants
 - ↑ insensible water loss
 - ↑ heat loss
 - ↑ risk for infection
 - ↑ risk for trauma

Skin...



Medications

- Epinephrine for persistent bradycardia despite successful other resuscitative measures
- Naloxone – CAUTION – NOT recommended by AAP/NRP
 - 0.1mg/kg IO/ET
 - Half-life shorter than most opioids!!

Epinephrine

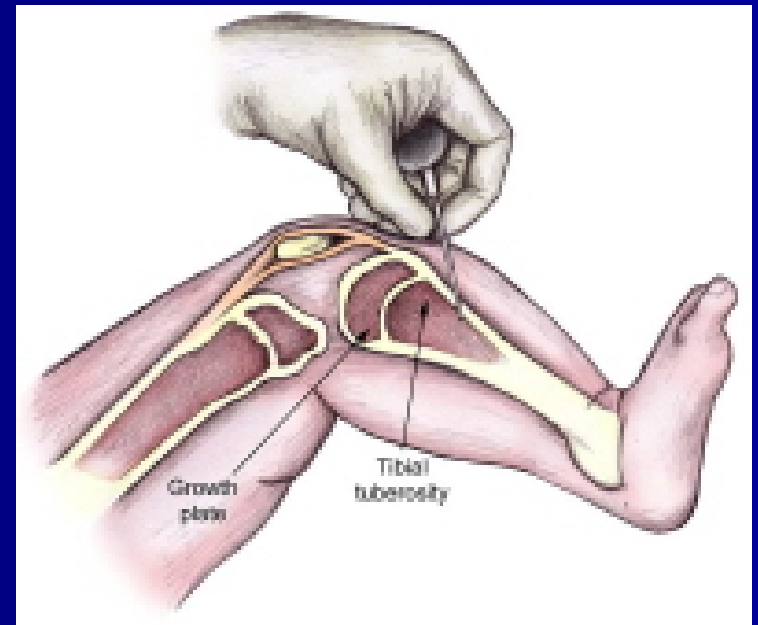
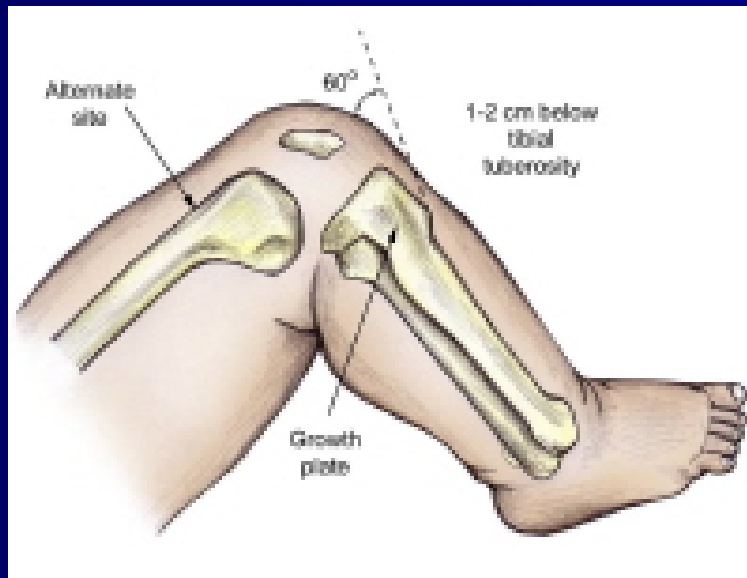
- Recommended dose is 0.01-0.03mg/kg i.v. or IO
- If no i.v. access available, 0.05-0.1mg/kg may be used endotracheally
- Epinephrine is acidic
- Needs a “flush” 0.5ml NS
- Uncertain dose administered
- Interferes with CO2 detector use

Intra-Osseus Access

- A good choice in infants if IV access unavailable
- Different kinds
 - Jamshidi – type
 - EZ IO – babies >5kg
 - Cook type



IO insertion



Outline

- The Basics of Neonatal Resuscitation
- *Field Considerations*
- The Neonatal Airway
- Basic Neonatal Airway Management
- Airway Abnormalities
- Prehospital Management of Airway Emergencies and Respiratory Diseases

Field Considerations (1)

■ Temperature control

- Hypothermia common, causes include:
 - Birth significantly prior to EMS arrival
 - Birth on transport (private car, ambulance)
 - Birth in area without heating (unheated home)
 - Baby remains in wet/exposed environment
- Remedies:
 - Dry infant
 - Place on mother's chest/abdomen (direct skin contact)
 - Heated blankets

Field Considerations (2)

- Blood loss due to delayed clamping
 - Signs include:
 - Pallor, mottled skin, delayed capillary refill time (>4secs), tachycardia, hypotension
 - Frequently accompanied by hypothermia
 - Hypothermia signs may mask signs of hypovolemia
 - Remedy:
 - Volume expansion (normal saline, 10ml/kg)
 - Emergent low-lying umbilical catheter
 - Insert umbilical catheter to 3-4cm (term) or UNTIL BLOOD RETURN, no further
 - IO needle

Field Considerations (3)

- Infection risk
 - Primarily affected by location of delivery
 - Baby born in toilet etc.
 - Not usually immediately life-threatening if acquired post-natally
 - May be prompting pre-term birth
 - May present as hypotension and shock
 - Requires immediate hospital attention

Field Considerations (4)

- Remember sugar!
 - Infants have decreased reserves and/or increased glucose utilization
 - More so in cases of small for gestational age or large for gestational age infants, or in particularly stressed neonates
 - Start D10W at 80ml/kg/day (roughly 4ml/kg/hr) after initial fluid resuscitation

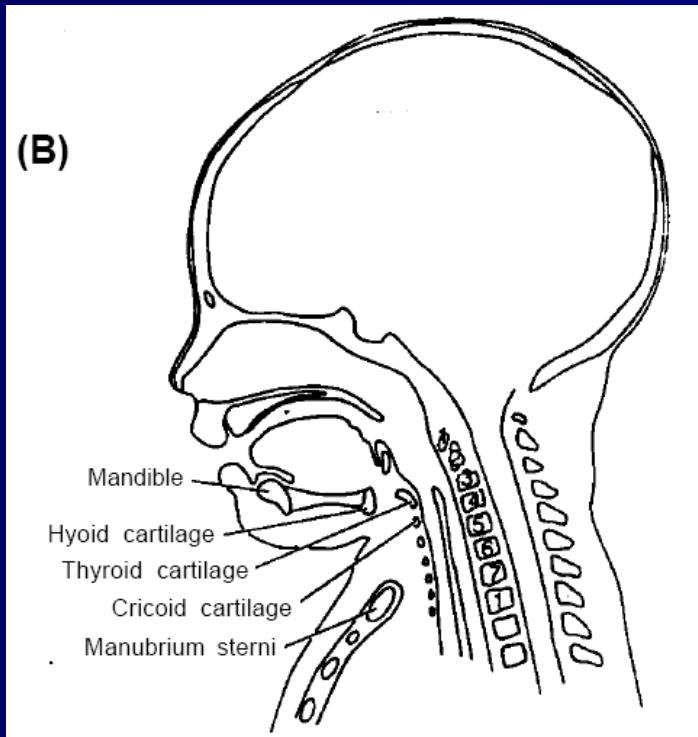
Outline

- The Basics of Neonatal Resuscitation
- Field Considerations
- *The Neonatal Airway*
- Basic Neonatal Airway Management
- Airway Abnormalities
- Prehospital Management of Airway Emergencies and Respiratory Diseases

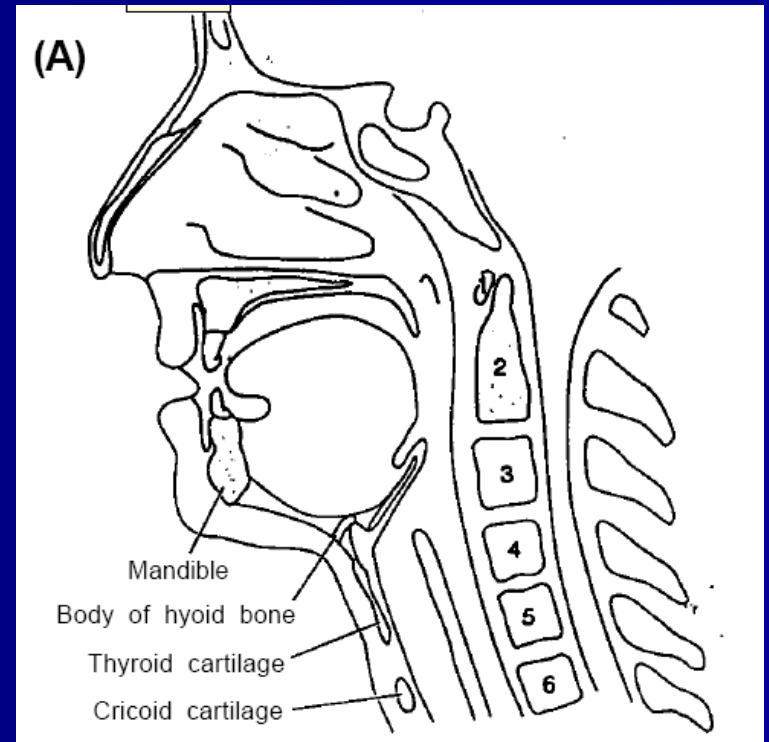
The Neonatal Airway

- More anterior and superior than pediatric or adult
- Higher in the neck at birth
 - Birth laryngeal level C1-C4
 - Laryngeal level age 6-adult C4-C7
- Narrowest part is the area of the cricoid cartilage in 93%
- Vocal cords are likely to be mucosal in color or light pink, NOT white
- Long epiglottis

Anatomy of the Neonatal Airway

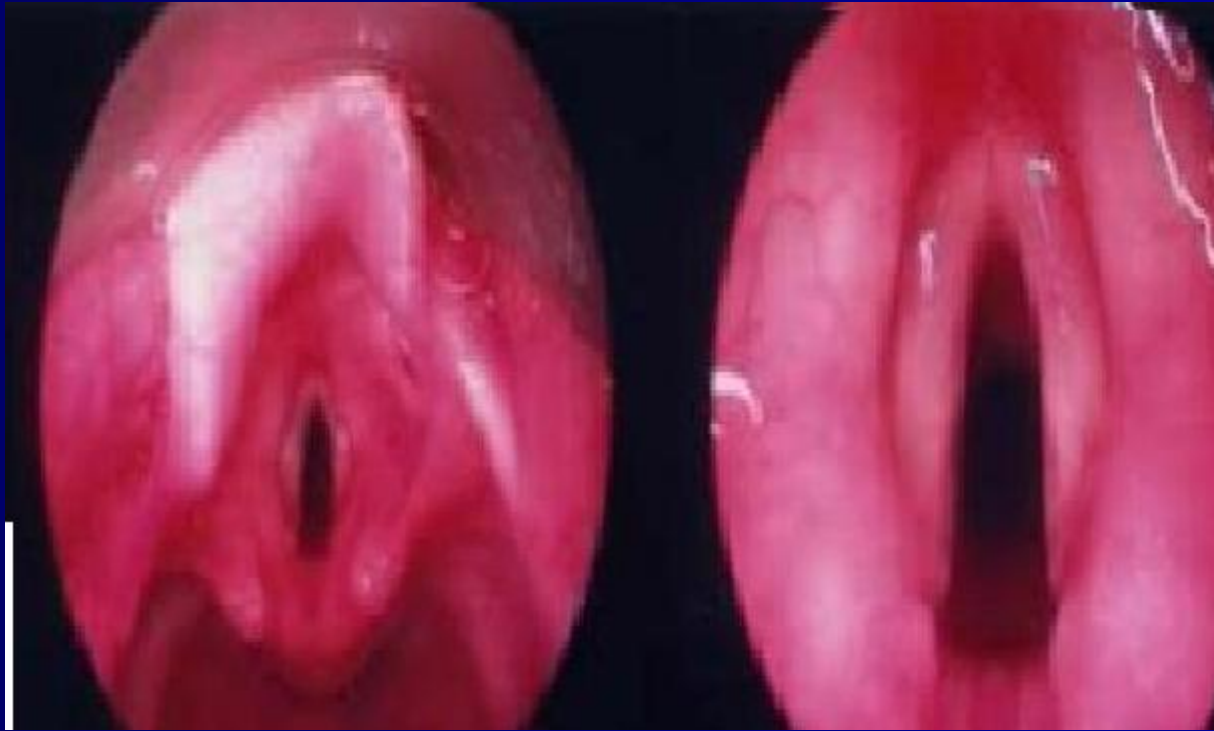

Neonatal Airway



Adult Airway

Laryngoscopic View



Outline

- The Basics of Neonatal Resuscitation
- Field Considerations
- The Neonatal Airway
- ***Basic Neonatal Airway Management***
- Airway Abnormalities
- Prehospital Management of Airway Emergencies and Respiratory Diseases

Newborns and the airway

- Majority of infants' 'arrests' are respiratory
- Focus on airway and breathing
 - Infant positioning
 - Tactile stimulation
 - Positive pressure ventilation
- Neonatal Resuscitation Program (NRP) guideline:
 - No CPR until >30 secs EFFECTIVE PPV
 - MR SOPA

MR SOPA (or MRS OPA)

- Mask – verify size
- Reposition mask and/or baby
- Suction
- Open mouth
- Pressure – increase if no chest rise
- Adjunct airway – consider ETT/LMA if all fails

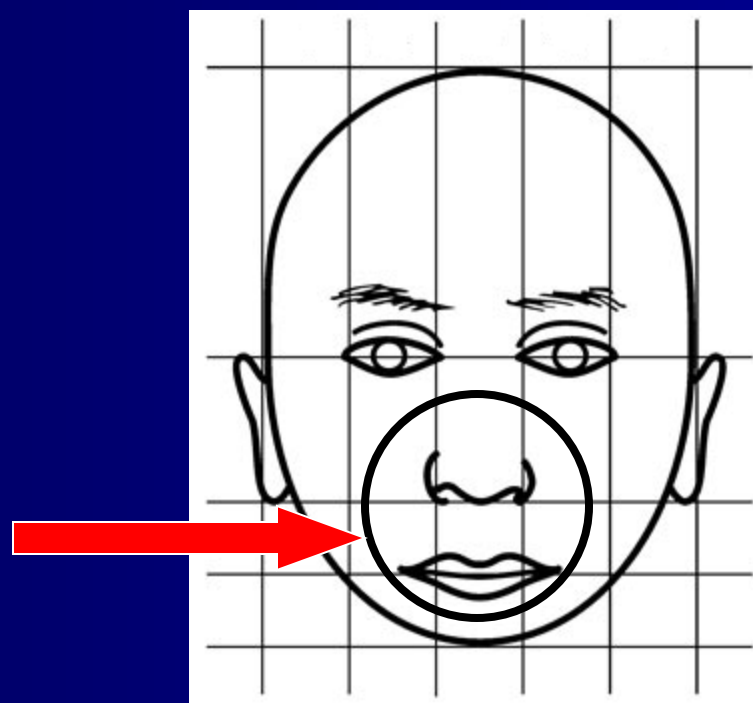
Bag-Mask Ventilation

- Choosing the appropriate size mask
- Infant positioning
- Ventilation pressures

Mask Choice

- The correct size is determined by facial/infant size and fit
- The mask should cover the nose and mouth
- Do NOT apply pressure in the following places:
 - over the eyes (mask too large) – will prompt vagally mediated bradycardia
 - nose (mask too small) – will obstruct nose, decreased ability to ventilate
 - overlap beyond the chin (mask too large) – inability to obtain a good seal, persistent leak, inability to ventilate

Appropriate Mask Positioning

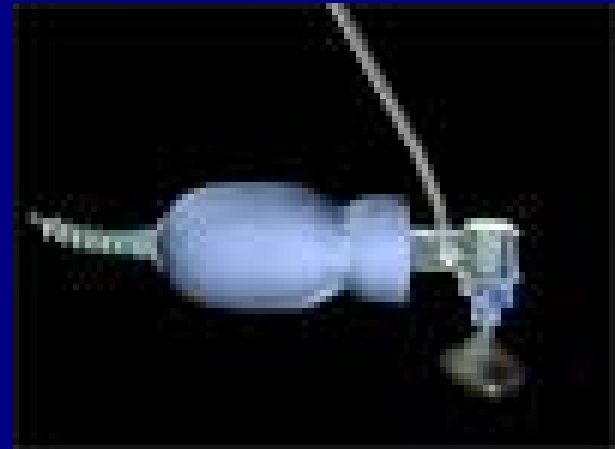


Vagal Tone

- Highly sensitive to vagal stimuli
- Avoid pressure over eyes, rectal temperatures, deep suction
- Rapid decompensation with vagal stimulation
 - Bradycardia
 - Desaturation
- Rapid resolution if stimulus ceases

Equipment

- Self-inflating (a.k.a. Ambu Bag):
 - Use room air or O₂
 - Use reservoir for O₂
 - Must add manometer
 - PEEP valve available
 - Different sizes available
 - Neonate (250ml)
 - Pediatric (500ml)
 - Adult 2000ml



To Tube or Not to Tube...

- Data not supporting routine intubation
 - Traumatic intubation
 - Delay in transport
 - Accidental extubations
 - Complications of endotracheal intubation
 - Right mainstem
- Ability to support many infants with BVM

Endotracheal Intubation

- Equipment:
 - Mask, bag, suction, stethoscope
 - Appropriately sized Miller straight blade laryngoscope
 - Appropriately sized infant (uncuffed) endotracheal tube
 - End-tidal CO₂ detector (if available)

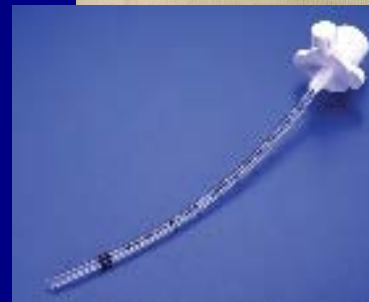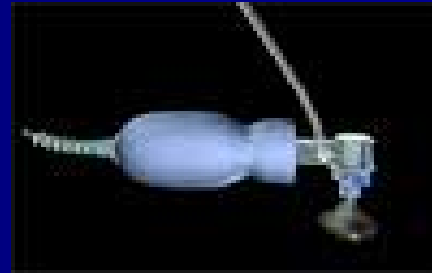
Endotracheal Intubation

■ When?

- Apnea, respiratory failure, hypoxia not responsive to PPV
- Prolonged (>5min) need for CPR
- Airway abnormalities requiring intubation (CDH, PPHN, vocal cord paralysis...)

Endotracheal Intubation

- Equipment
 - Bag-valve-mask
 - Laryngoscope
 - Endotracheal tube
 - Suction
 - Stethoscope
 - Extra hands
 - Drugs



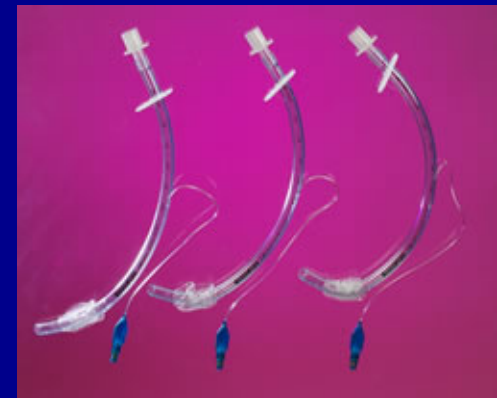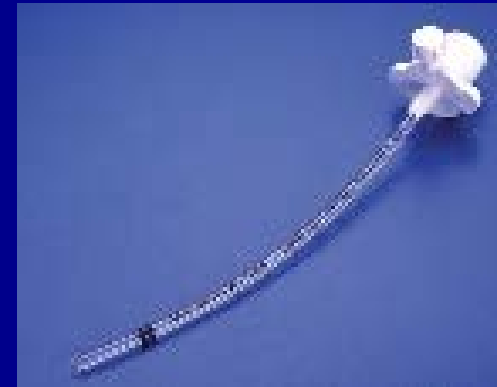Laryngoscope Choice

- Miller 0 blade:
 - <34 weeks
 - <2 kg
- Miller 1 blade:
 - >34 weeks
 - >2 kg

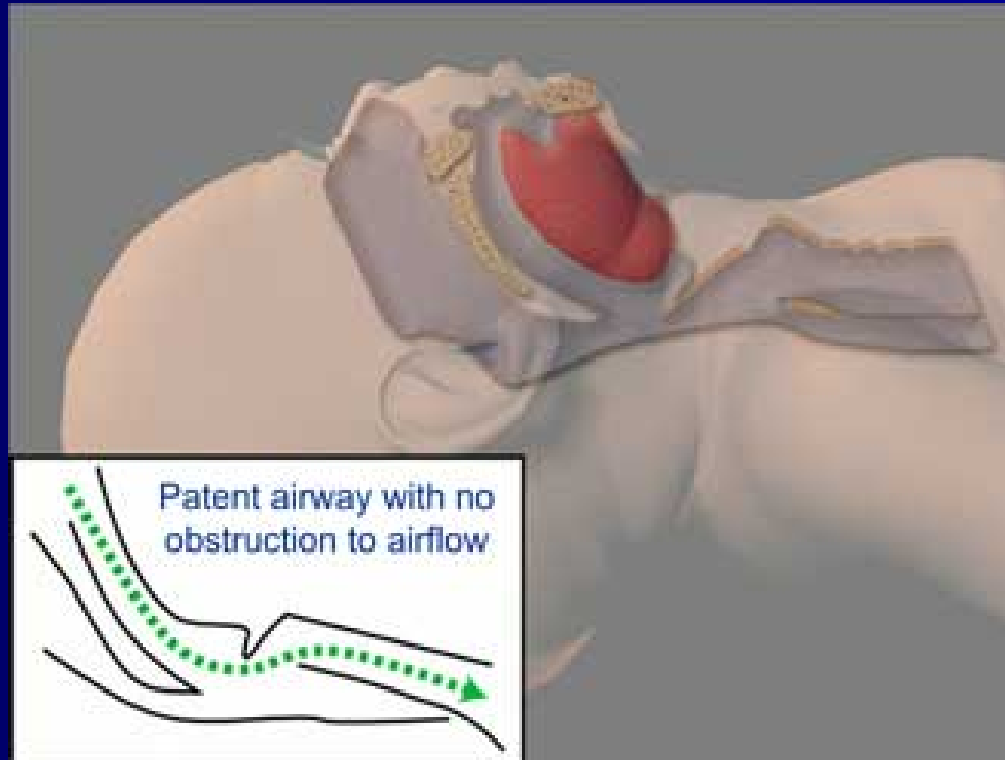


Endotracheal Tubes

- Neonatal ETT:
 - Constant diameter
 - Uncuffed
- Pediatric/Adult ETT:
 - Can be tapered
 - Cuffed



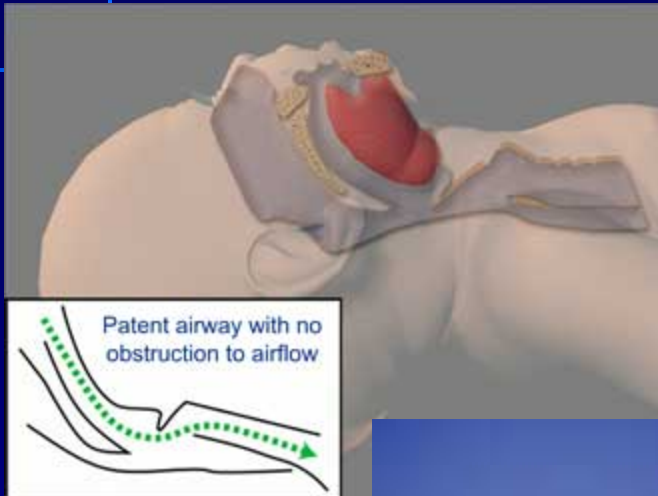
Infant positioning



Endotracheal Tube Depth

- Vocal cord marker at the vocal cords
- 1, 2, 3... 7, 8, 9
 - 1, 2, or 3 kg, 7, 8 or 9 cm at the lip (or fraction thereof)
- Symmetrical breath sounds

Endotracheal Intubation



- 2.5Fr <1kg
- 3.0Fr 1-2kg
- 3.5Fr >2kg

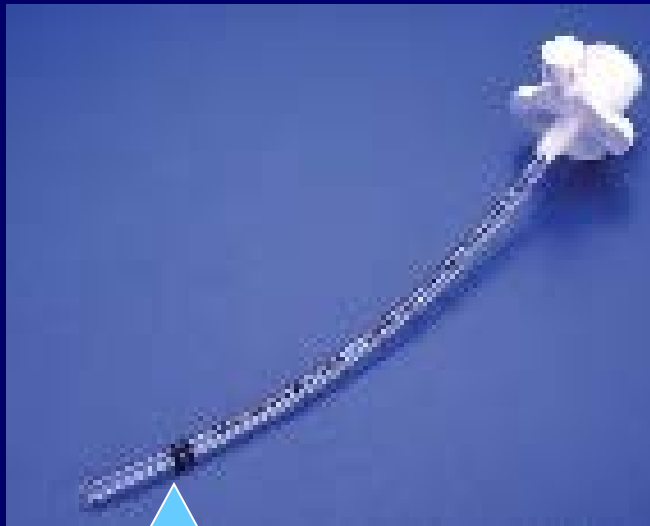- Vocal cord marker at the vocal cords

- 1, 2, 3... 7, 8, 9!!!
- Check placement!
 - Auscultate, CO2 detector, improvement, condensation

Evaluation of Successful Airway Management

- Condensate in the ETT
- Symmetrical breath sounds heard over the lung fields
- No breath sounds/distention over the abdomen
- End-tidal CO₂ detector color change
- The infant improves!

Endotracheal Tube Evaluation Tools



Vocal Cord Marker



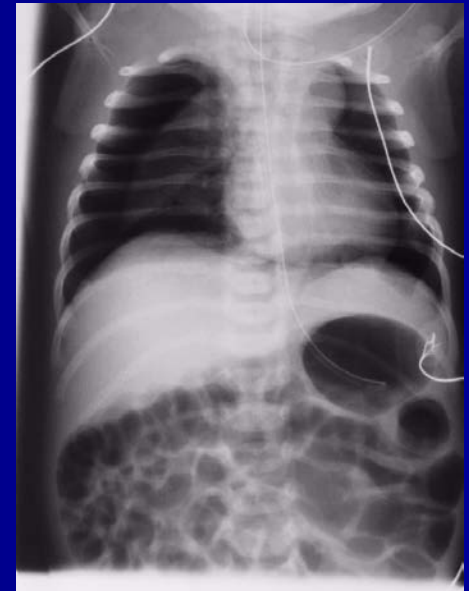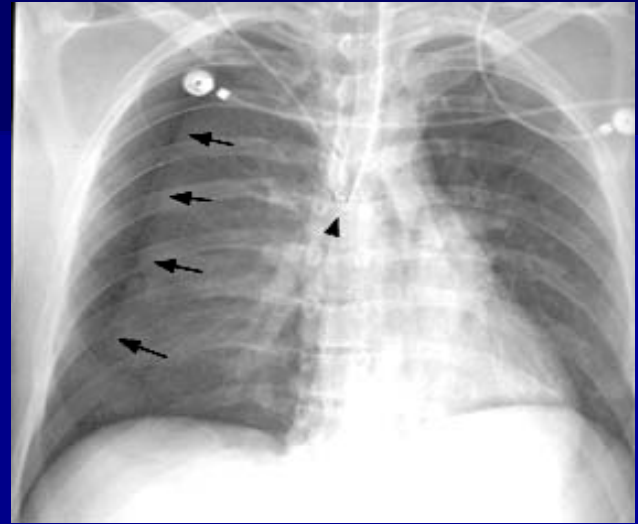
End-tidal CO2 detector

Ventilation Pressures

- Starting pressures
 - PEEP 4-6cm H₂O (if a PEEP valve is available)
 - PIP enough for **SUBTLE** chest rise (attempt to keep <20cm H₂O) and clinical improvement
 - NOT high pressures – increased risk for air leak/pneumothorax
- Adjust if...
 - Clinical deterioration, no chest rise...
 - Check ETT placement, continue to worry about pneumothorax

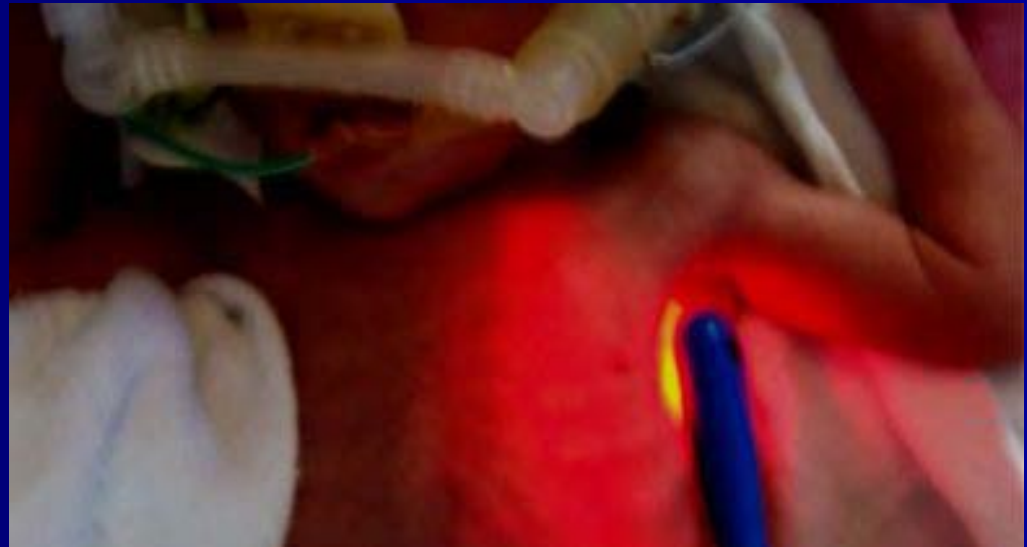Pneumothorax

- Missing lung markings at periphery
- May be accompanied by acute desaturations, difficulty ventilating, vascular instability
- May transilluminate
- Resolves after needle aspiration/chest tube placement



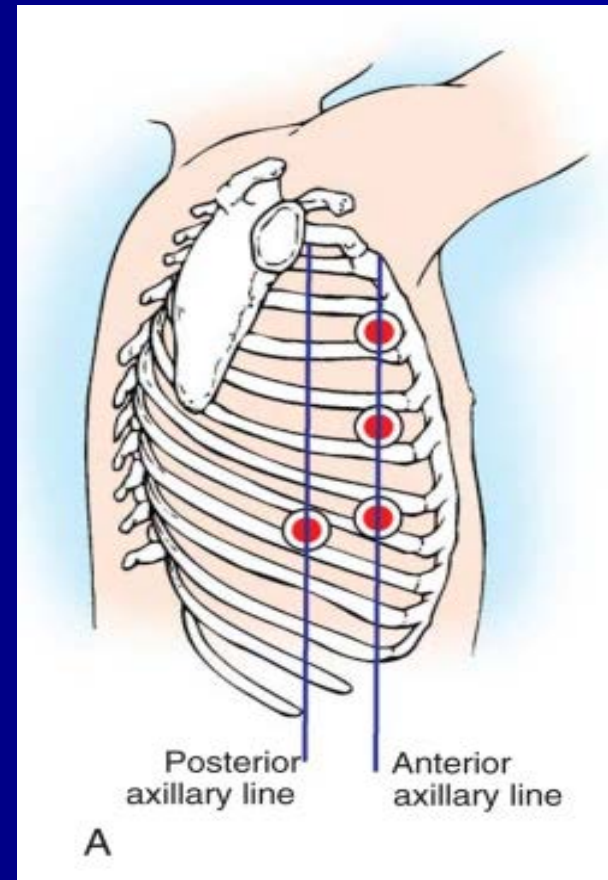
In Practice...

- Asymmetrical chest rise and breath sounds
- Narrowed pulse pressure
- Shifted PMI



Needle Aspiration of Pneumothorax (new NRP)

- 4th intercostal space
- Anterior axillary line
- Avoid neuromuscular bundle
- May use angiocath-stopcock method for ongoing evacuation



Outline

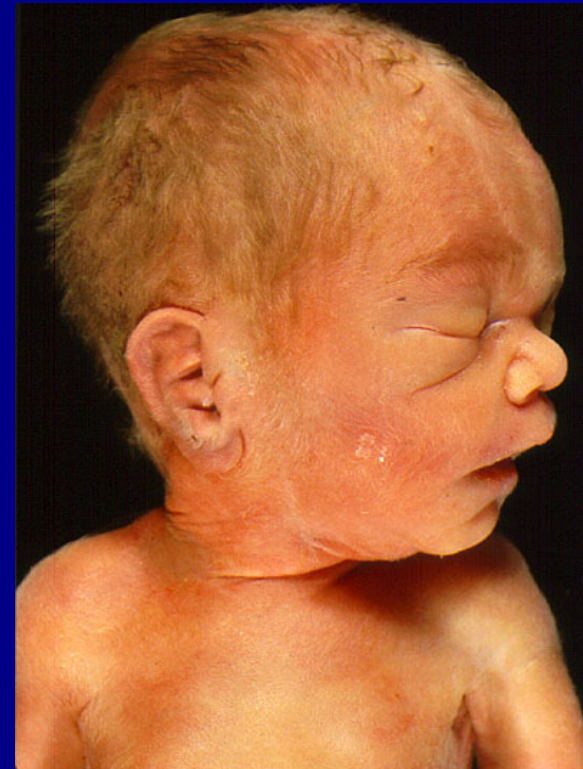- The Basics of Neonatal Resuscitation
- Field Considerations
- The Neonatal Airway
- Basic Neonatal Airway Management
- *Airway Abnormalities*
- Prehospital Management of Airway Emergencies and Respiratory Diseases

Airway Abnormalities

- Craniofacial abnormalities
 - Micrognathia, retrognathia
 - Cleft palate
 - Choanal atresia
- Laryngeal abnormalities
 - Webs and clefts
 - Vocal cord paralysis
- Tracheal abnormalities
 - Complete tracheal ring
 - Tracheo-esophageal fistula

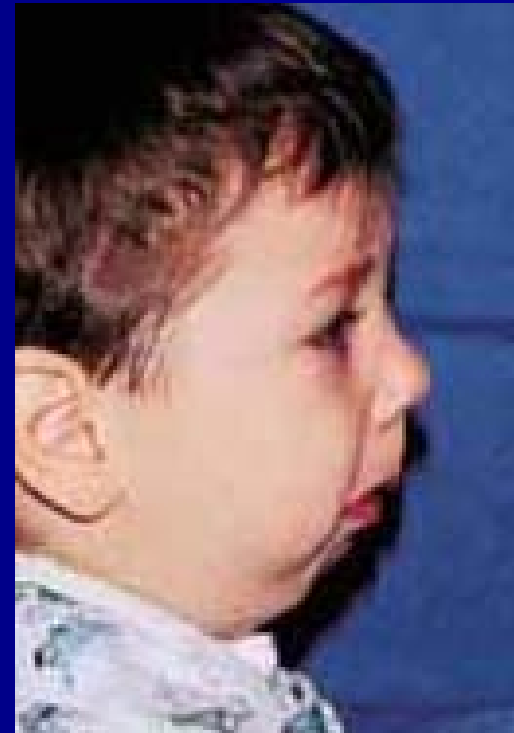Craniofacial abnormalities

- Micrognathia, retrognathia
 - Can be associated with syndromes such as Pierre-Robin sequence, Trisomies, Smith-Lemli-Opitz
 - Results in airway obstruction due to large tongue compared to mandible/mouth



Craniofacial abnormalities

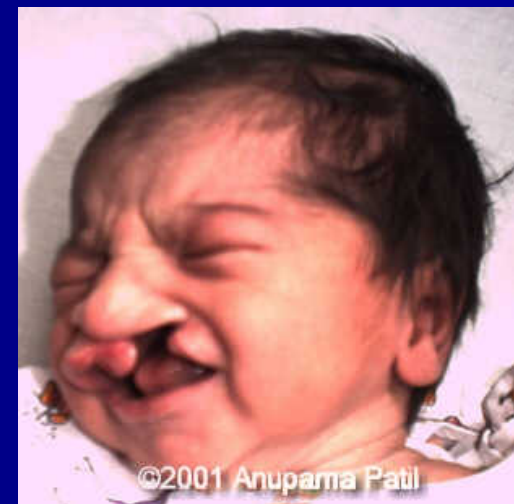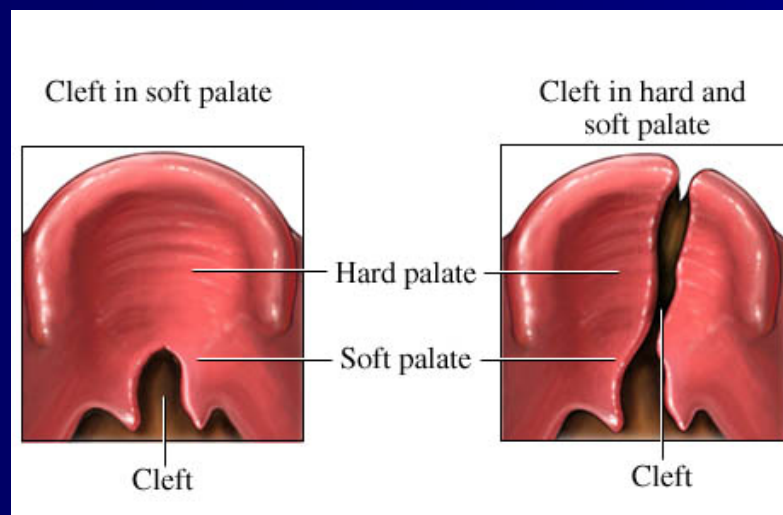
- Micrognathia, retrognathia
 - Intubation may be difficult due to limited jaw range-of-motion
 - Airway may be improved via prone positioning and oral airway or ETT use as nasal-to-posterior oropharyngeal airway



Craniofacial abnormalities

■ Cleft palate

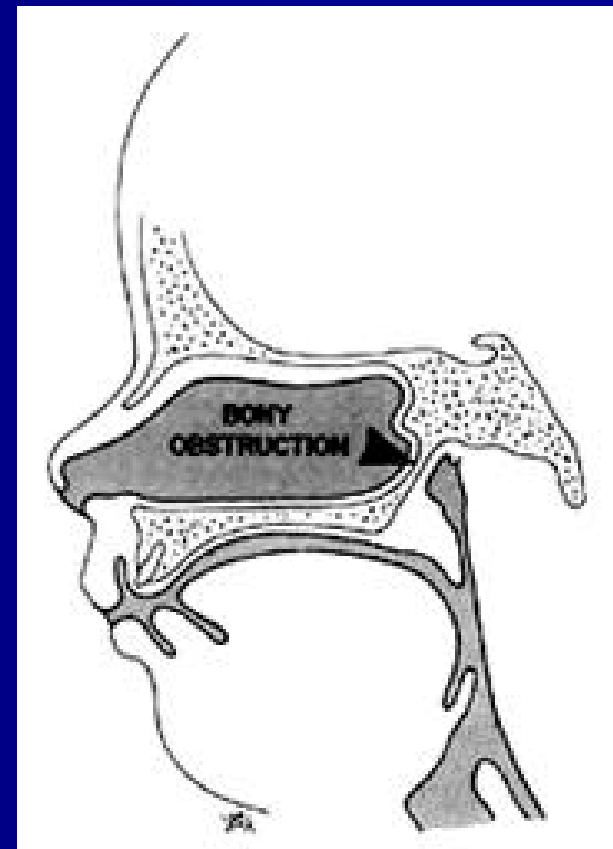
- Should not require increased airway support based purely on anatomy
- Usually able to intubate fairly easily
- Difficulties frequently encountered due to ‘optical illusions’



Craniofacial abnormalities

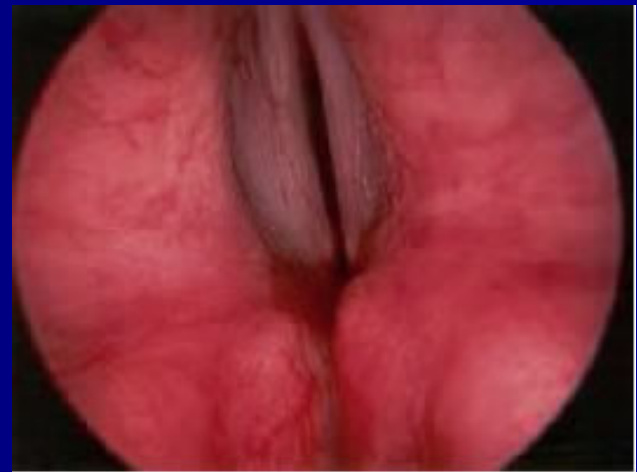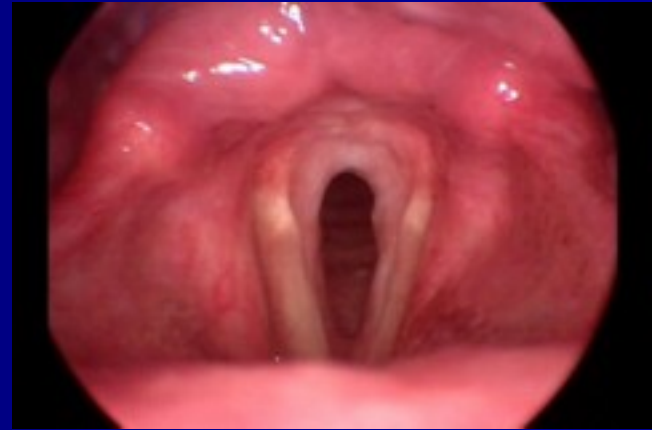Choanal atresia

- Normal appearing infant
- Blue at rest, but pinks with crying/screaming
- May be lethal if not recognized
- Treatment via oral airway



Laryngeal Abnormalities

- Laryngeal web
 - Stridor/respiratory distress
 - May result in difficult intubation
 - Smaller airway diameter than anticipated
- Vocal cord paralysis
 - Idiopathic or the result of traumatic delivery
 - Respiratory failure at birth



Tracheal Abnormalities

- Complete tracheal ring
 - May show respiratory failure while extubated, but exceedingly low vent settings and no evidence of parenchymal disease
- Tracheo-esophageal fistula
 - Increased secretions, signs of aspiration
 - Failure to pass oro- or naso-gastric tube
 - Usually requires constant suction in pouch, not respiratory support

Outline

- The Basics of Neonatal Resuscitation
- Field Considerations
- The Neonatal Airway
- Basic Neonatal Airway Management
- Airway Abnormalities
- *Prehospital Management of Airway Emergencies and Respiratory Diseases*

Airway Emergencies

- Bilateral choanal atresia
 - Cyanotic at rest, gasping infant
 - Pinks with screaming
 - Requires oral airway
- Bilateral vocal cord paralysis
 - Requires intubation
 - May require tracheostomy

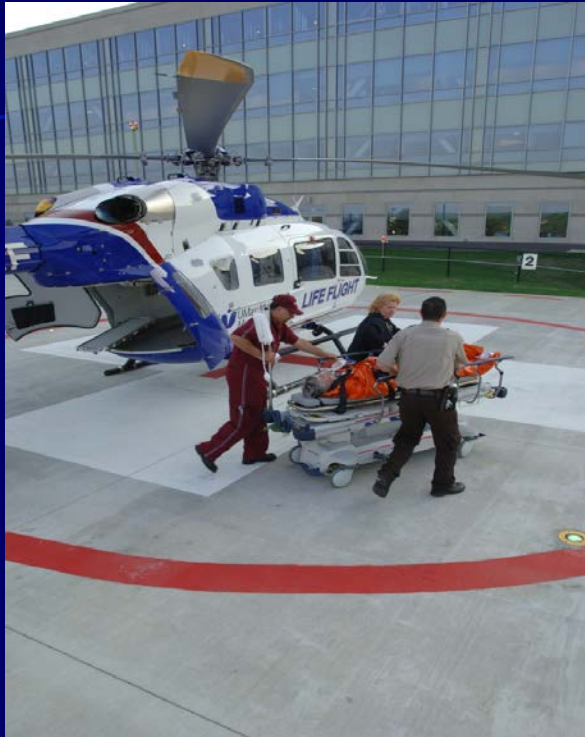Airway Emergencies

- C-spine transection/contusion
 - Think of in cases of severe respiratory failure/apnea in infant following difficult/traumatic/instrumented delivery
 - Poor prognosis
 - Requires PPV and immediate intubation

Meconium Aspiration Syndrome

- Meconium inactivates surfactant
- Ball-valve effect and patchy ventilation
- May lead to persistent pulmonary hypertension

Thank you for all you do!



Aren't you glad you are not medics here???

<http://www.youtube.com/watch?v=5SORYzaBLTI>

PS – all the comments said how cool this was and that they were trying to replicate this here!