Subtleties in the 12 lead ECG

Dave Grimsley
CCEMT-P, FP-C, AS

Virginia EMS Symposium 2009

Pegasus Flight Operations

Objectives

- Review cardiac anatomy
- Localize infarction and base treatment on anticipated complications
- Identify subtleties in the ECG related to PE, RVI, PWMI, Ext. Ant. MI
- Utilize criteria to differentiate SVT with aberrancy vs. VT

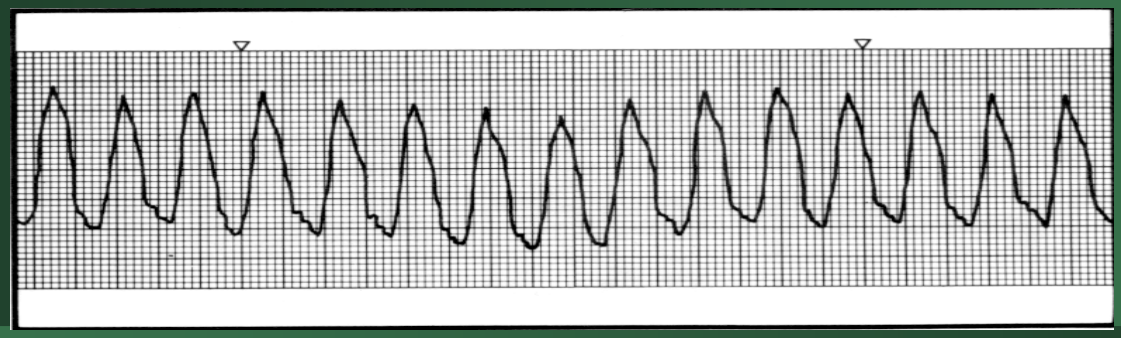

Right Coronary Artery

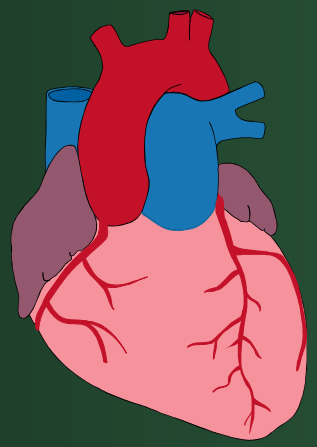

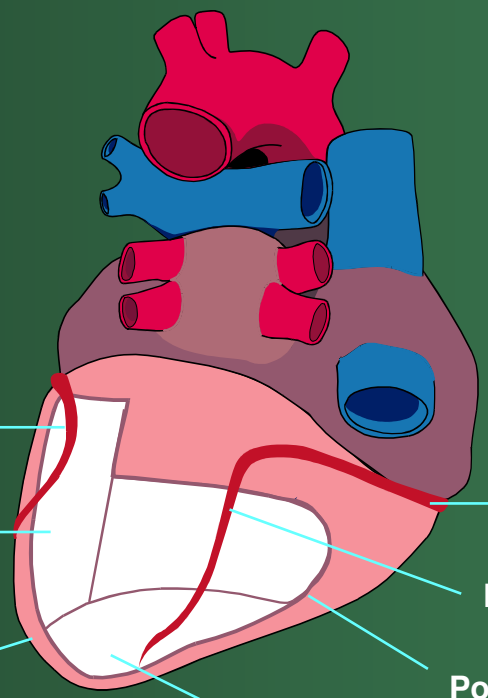

Right Coronary Artery (RCA)

- Proximal RCA
  - Right ventricle
  - Posterior wall
- AV nodal circulation
  - Supplied by RCA in 90% of population

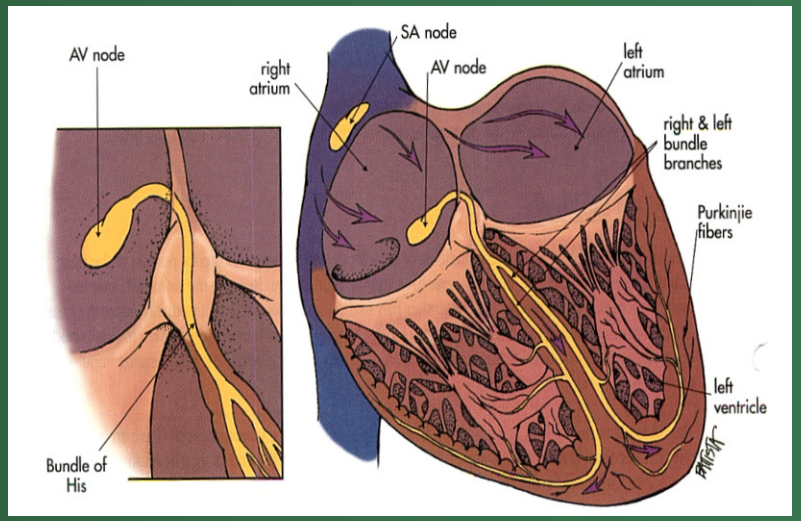

Left Coronary Artery

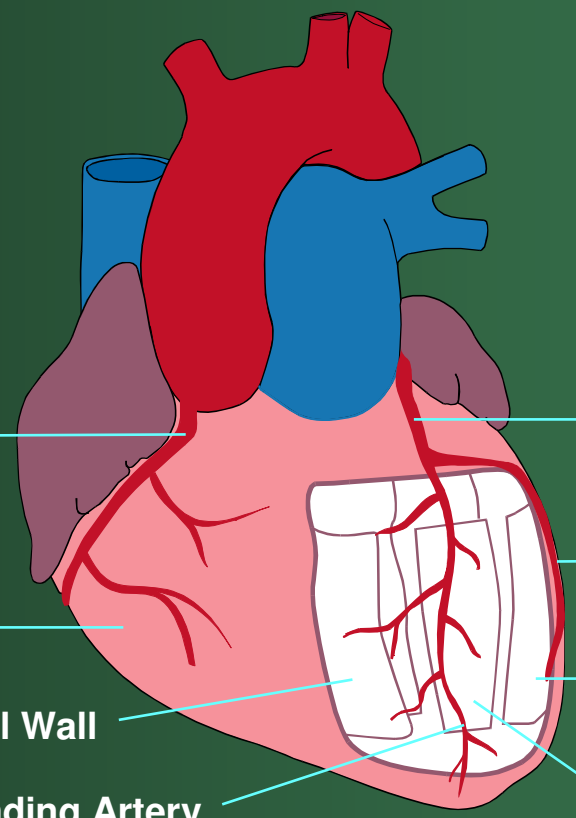

LCA Occlusions

- complications
  - Bundle branches supplied by LCA
  - Serious infra-nodal heart block may occur
  - Hemiblock

Localization of AMI important for Rx?

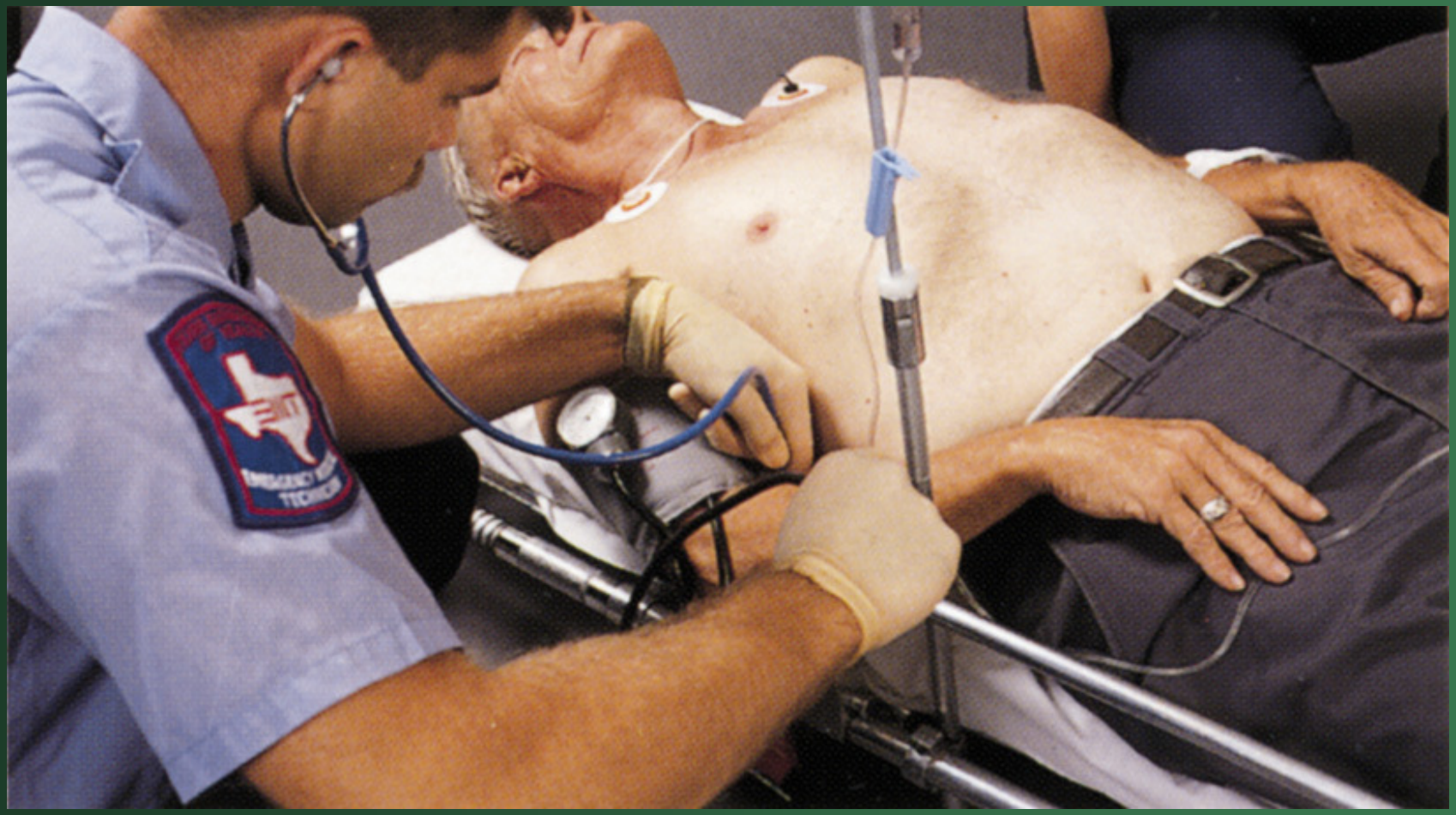

What kind of AVN blocks should be expected?

- RCAL
- Dysfunction at the AVN
- Use caution administering Atropine in setting of MI

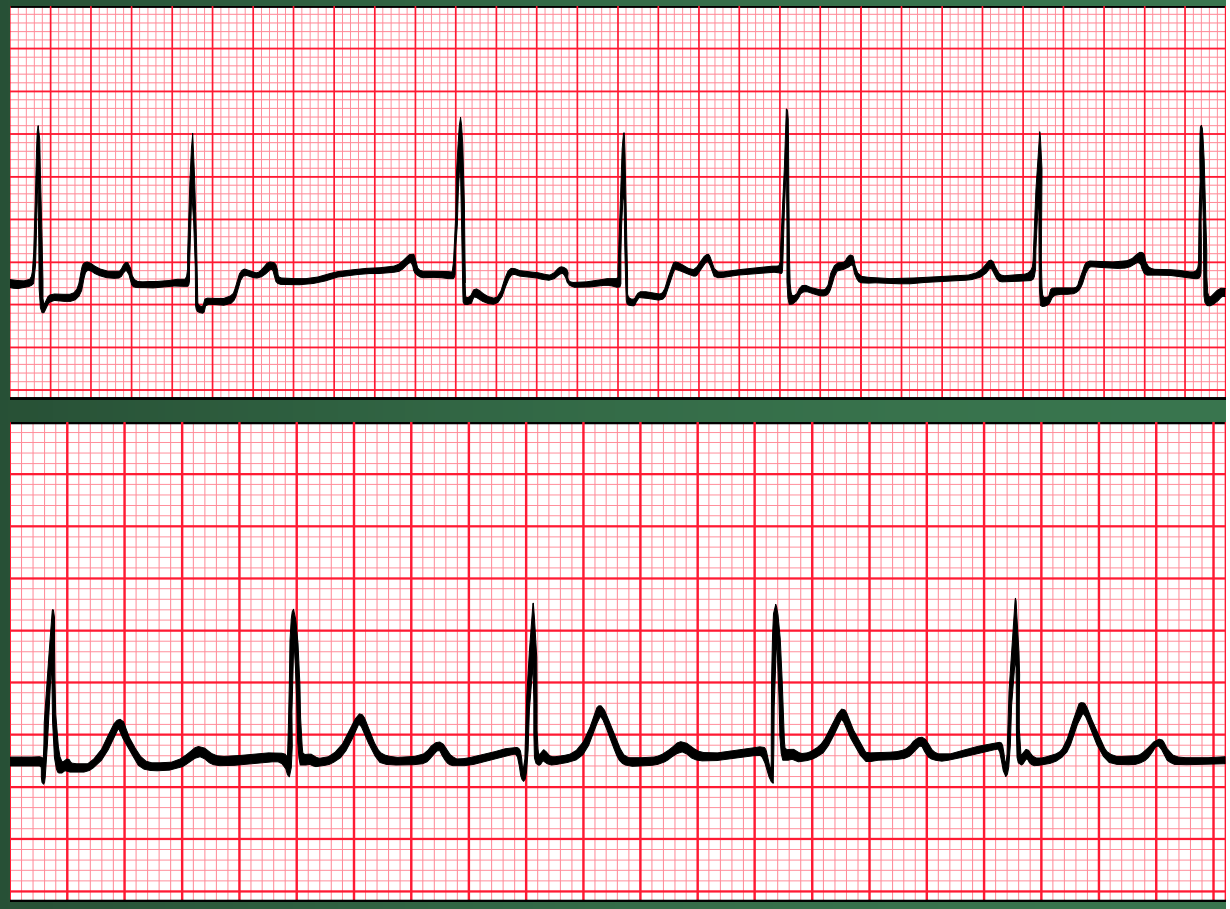

AVN blocks

- LCAL
- Infranodal block
- WQRS

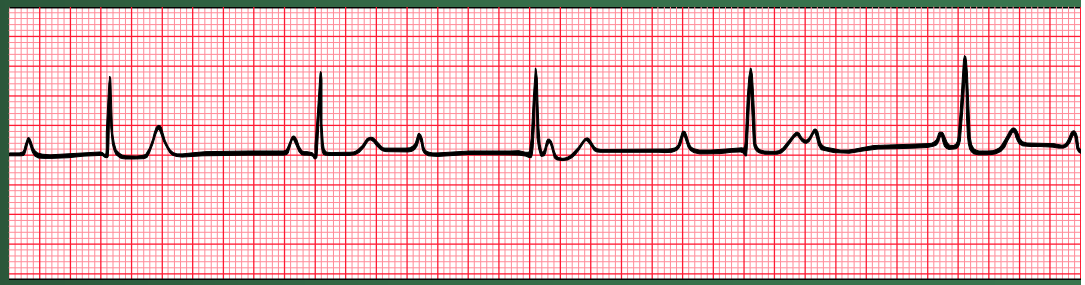

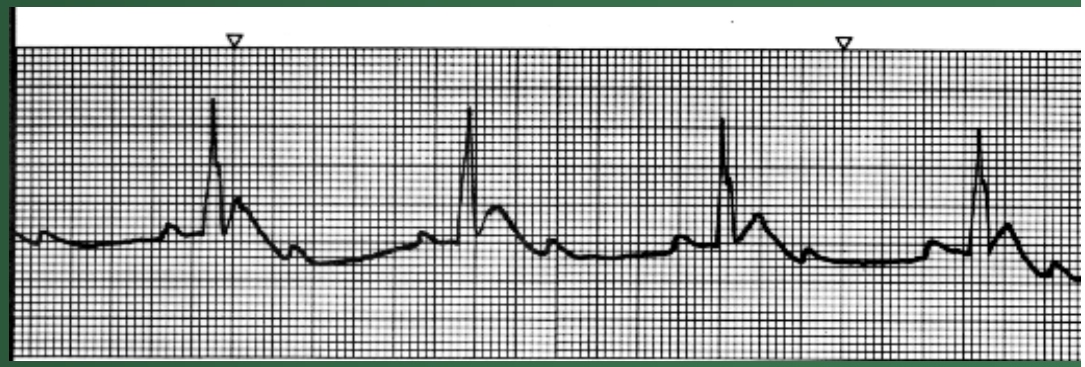

EVOLUTION OF INFARCTION

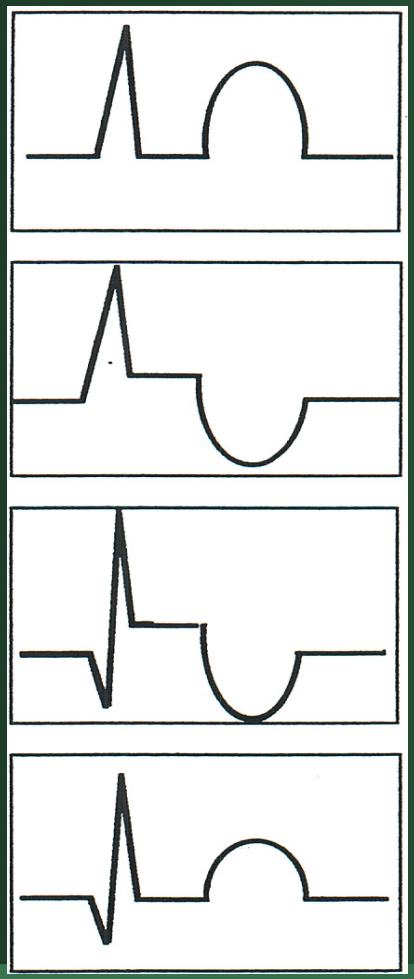

- Tall T wave
- ⇑ ST segment
- ⇓ T wave
- Pathologic Q wave
- EKG normalizes,
  Q wave remains as
  evidence of MI

EKG changes must be present in two or more anatomically contiguous leads to be indicative if MI!

Major Complications

Lead Groups

I	aVR	V1	V4
II	aVL	V2	V5
III	aVF	V3	V6

Limb Leads

Chest Leads

Inferior Wall

- II, III, aVF
  - Left Leg

I	aVR	V1	V4
II	aVL	V2	V5
III	aVF	V3	V6

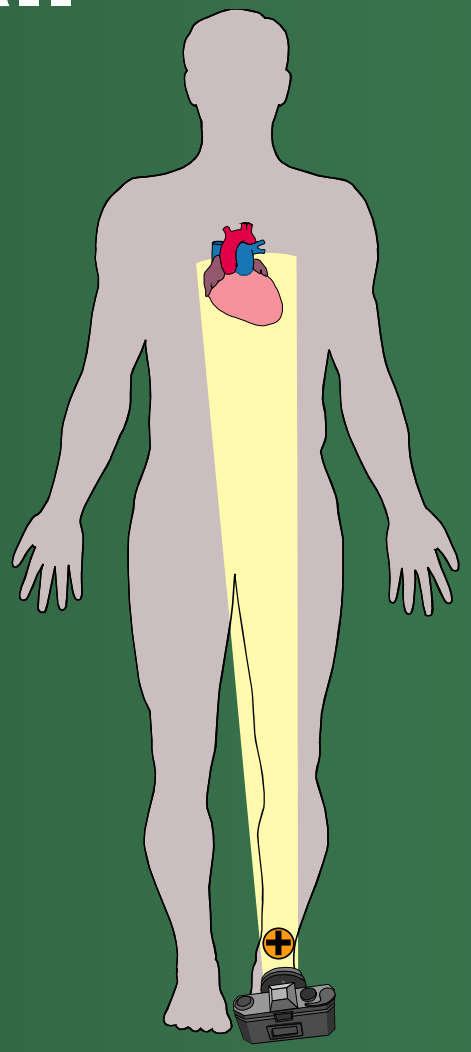

Inferior Wall

I	aVR	V1	V4
II	aVL	V2	V5
III	aVF	V3	V6

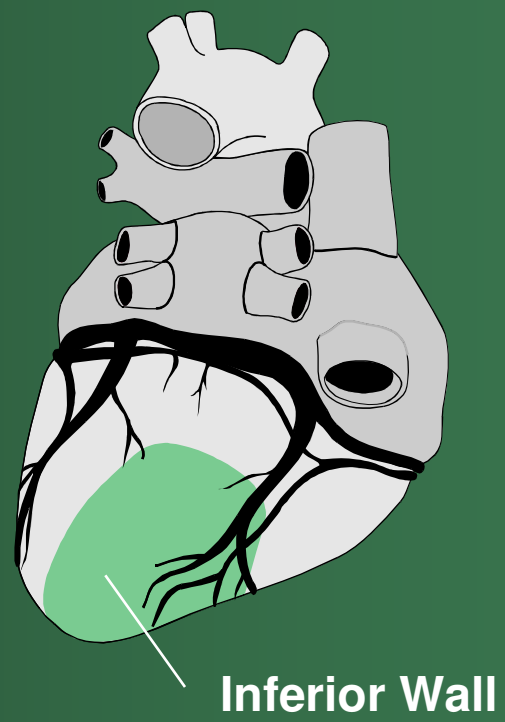

High Lateral Wall

- I and aVL
  - Left Arm

I	aVR	V1	V4
II	aVL	V2	V5
III	aVF	V3	V6

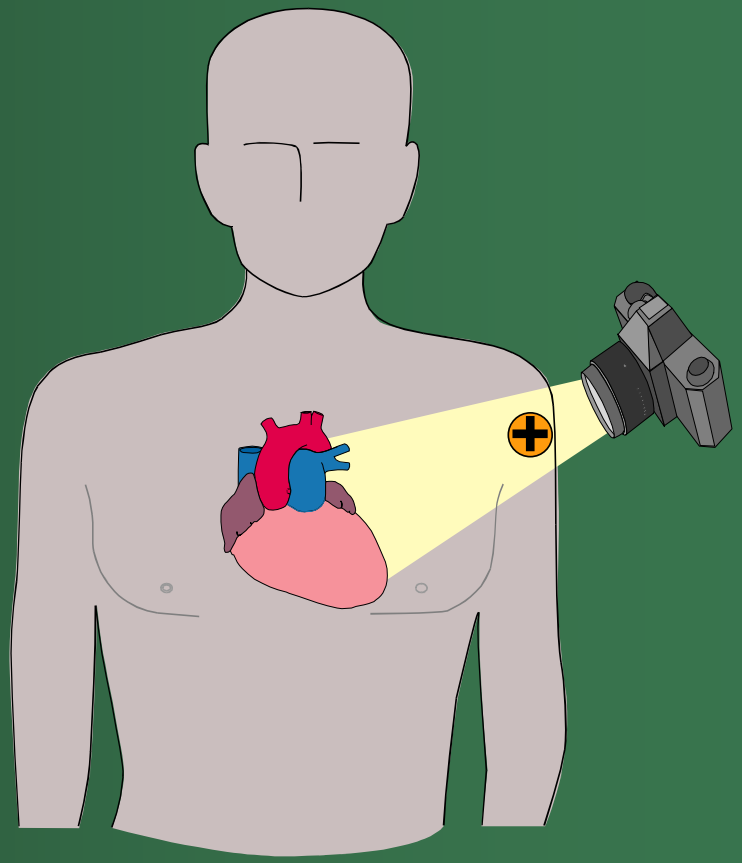

Lateral Wall

- V5 and V6
  - Left lateral chest
  - Circflx art.

I	aVR	V1	V4
II	aVL	V2	V5
III	aVF	V3	V6

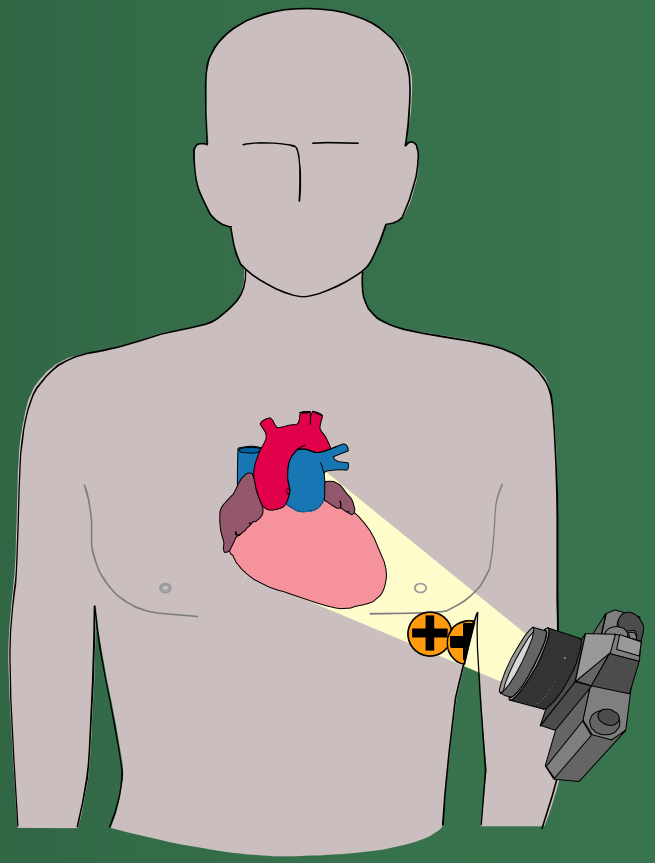

Lateral

I, aVL, V5, V6

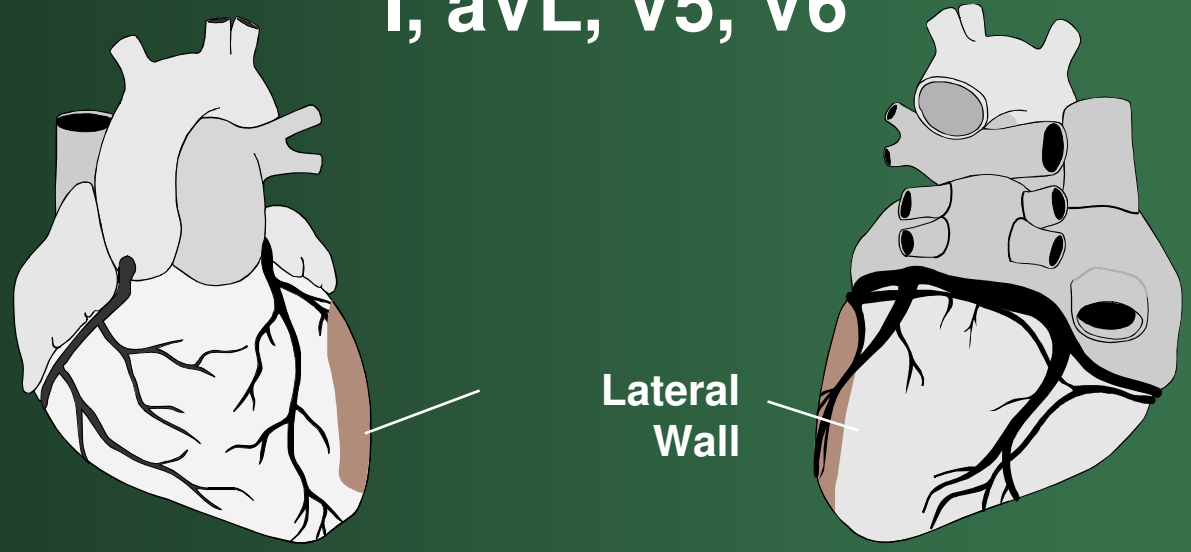

I	aVR	V1	V4
II	aVL	V2	V5
III	aVF	V3	V6

Anterior Wall

- V3, V4
  - Left anterior chest

I	aVR	V1	V4
II	aVL	V2	V5
III	aVF	V3	V6

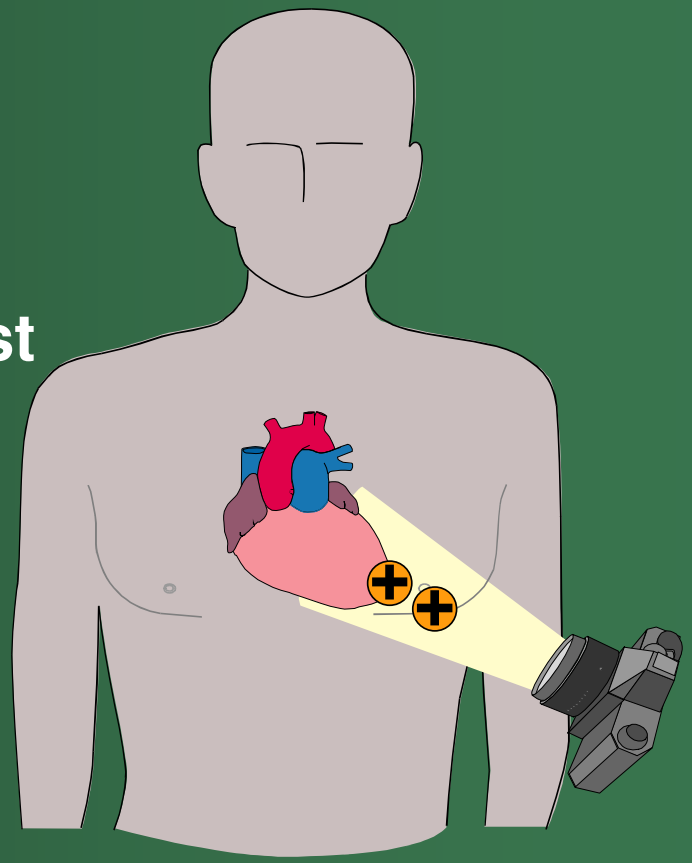

Anterior Wall

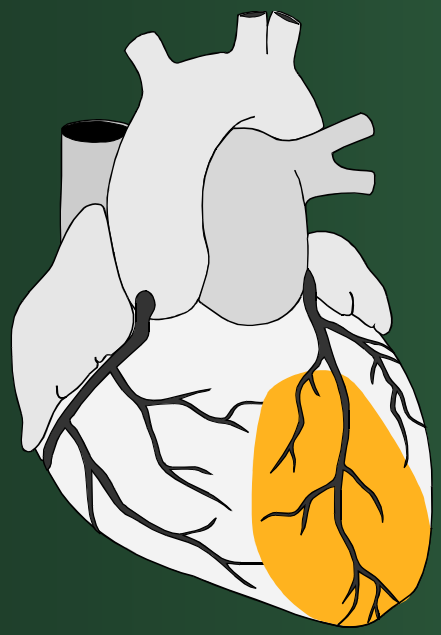

- V3, V4
- LAD art.

I	aVR	V1	V4
II	aVL	V2	V5
III	aVF	V3	V6

Septal Wall

- V1, V2
- Along sternal borders

I	aVR	V1	V4
II	aVL	V2	V5
III	aVF	V3	V6

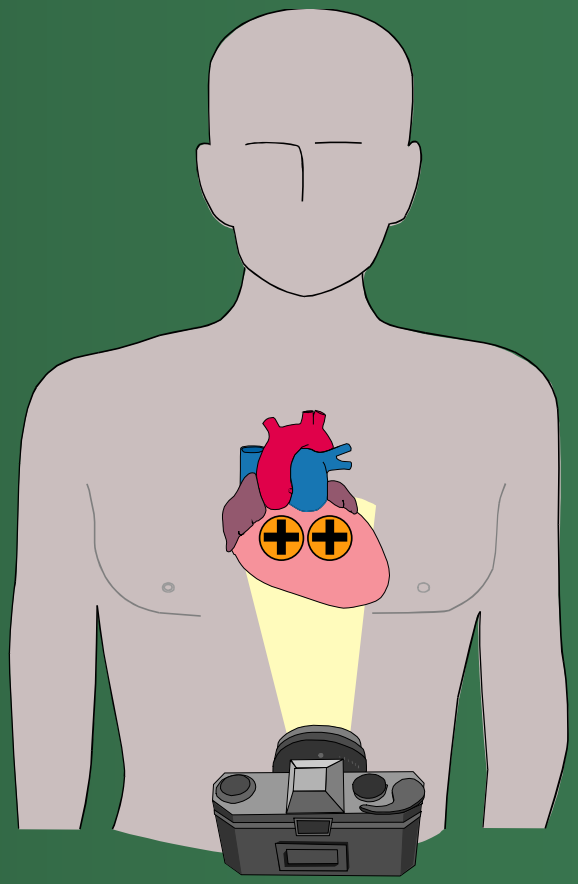

Septal

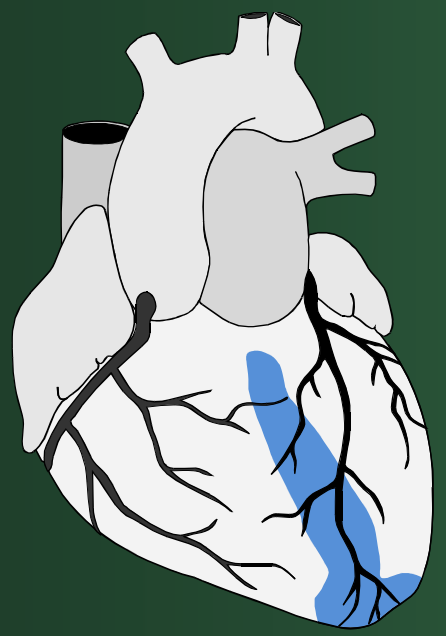

- V1,V2
- Septal brach of LAD

I	aVR	V1	V4
II	aVL	V2	V5
III	aVF	V3	V6

AMI Localization summary

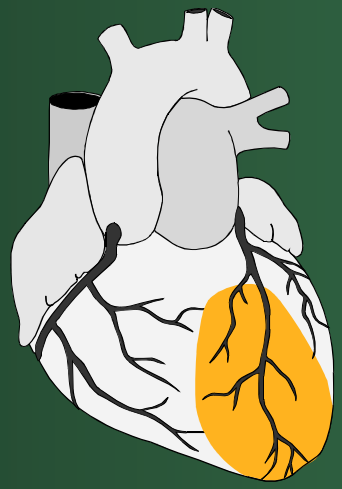

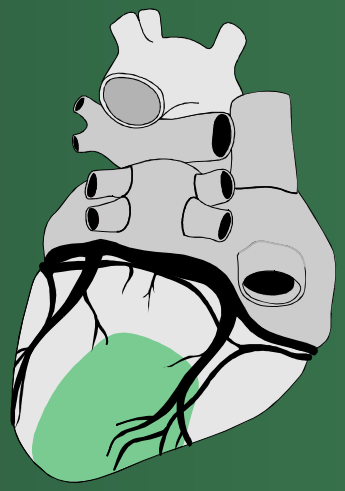

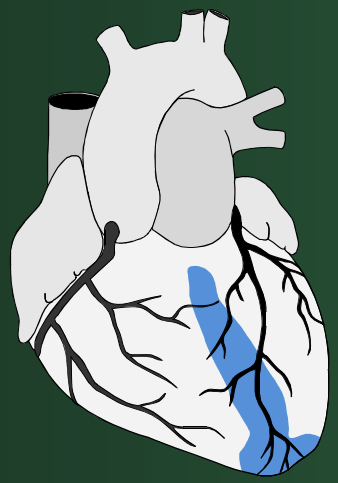

I	aVR	V1	V4
II	aVL	V2	V5
III	aVF	V3	V6

Anterior:	V3, V4
Septal:	V1, V2
Inferior:	II, III, AVF
Lateral:	I, AVL, V5, V6


WOULD YOU LIKE TO
KEEP THE EKG PADS
AS SOUVENIRS?
BERRY 97©

Practice

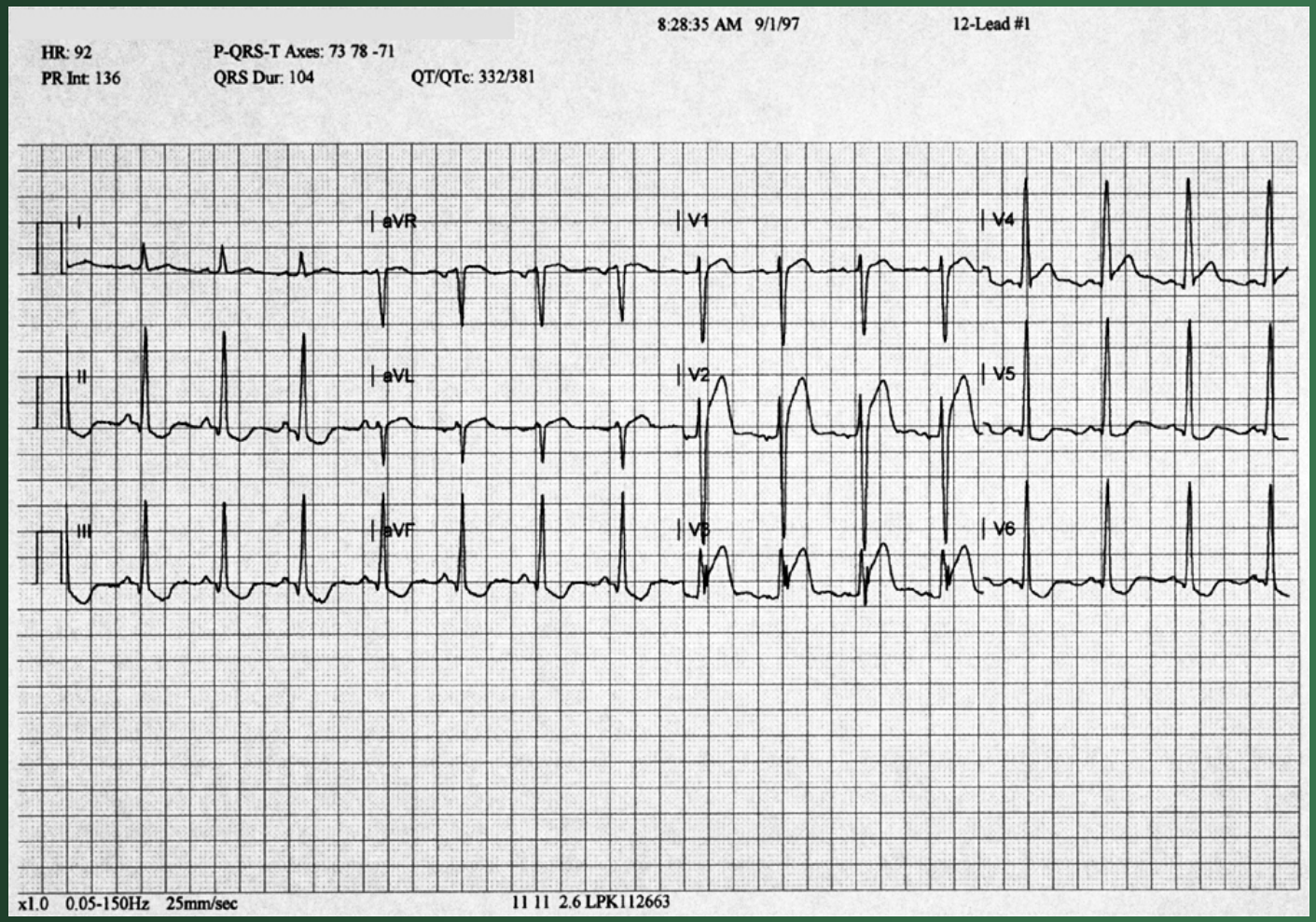
8:28:35 AM 9/1/97
12-Lead #1
HR: 92
PR Int: 136
P-QRS-T Axes: 73 78 -71
QRS Dur: 104
QT/QTc: 332/381
I
aVR
V1
V4
II
aVL
V2
V5
III
aVF
V3
V6
x1.0 0.05-150Hz 25mm/sec
11 11 2.6 LPK112663

Practice

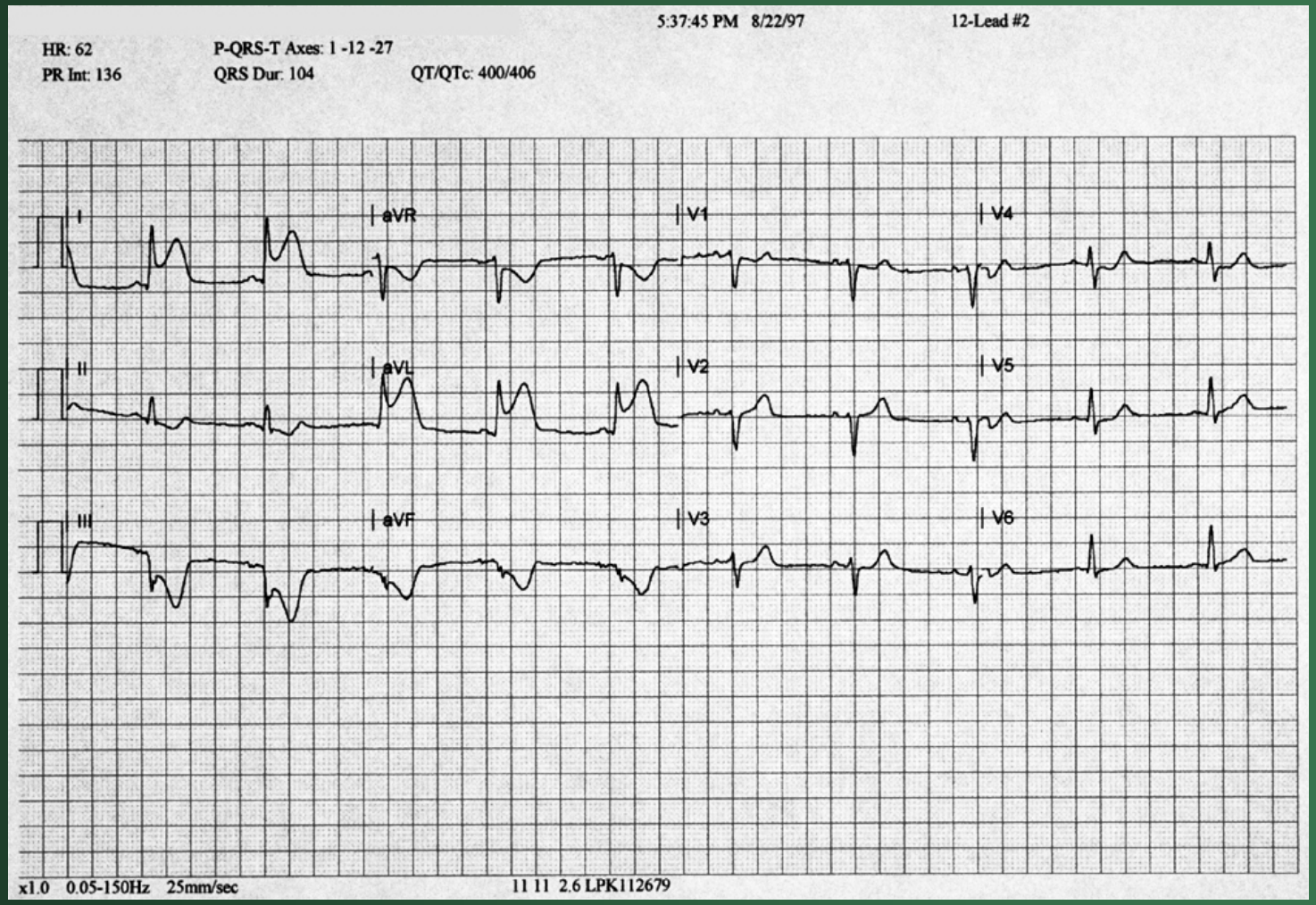
5:37:45 PM 8/22/97
12-Lead #2
HR: 62
PR Int: 136
P-QRS-T Axes: 1 -12 -27
QRS Dur: 104
QT/QTc: 400/406
I
aVR
V1
V4
II
aVL
V2
V5
III
aVF
V3
V6
x1.0 0.05-150Hz 25mm/sec
11 11 2.6 LPK112679

Practice

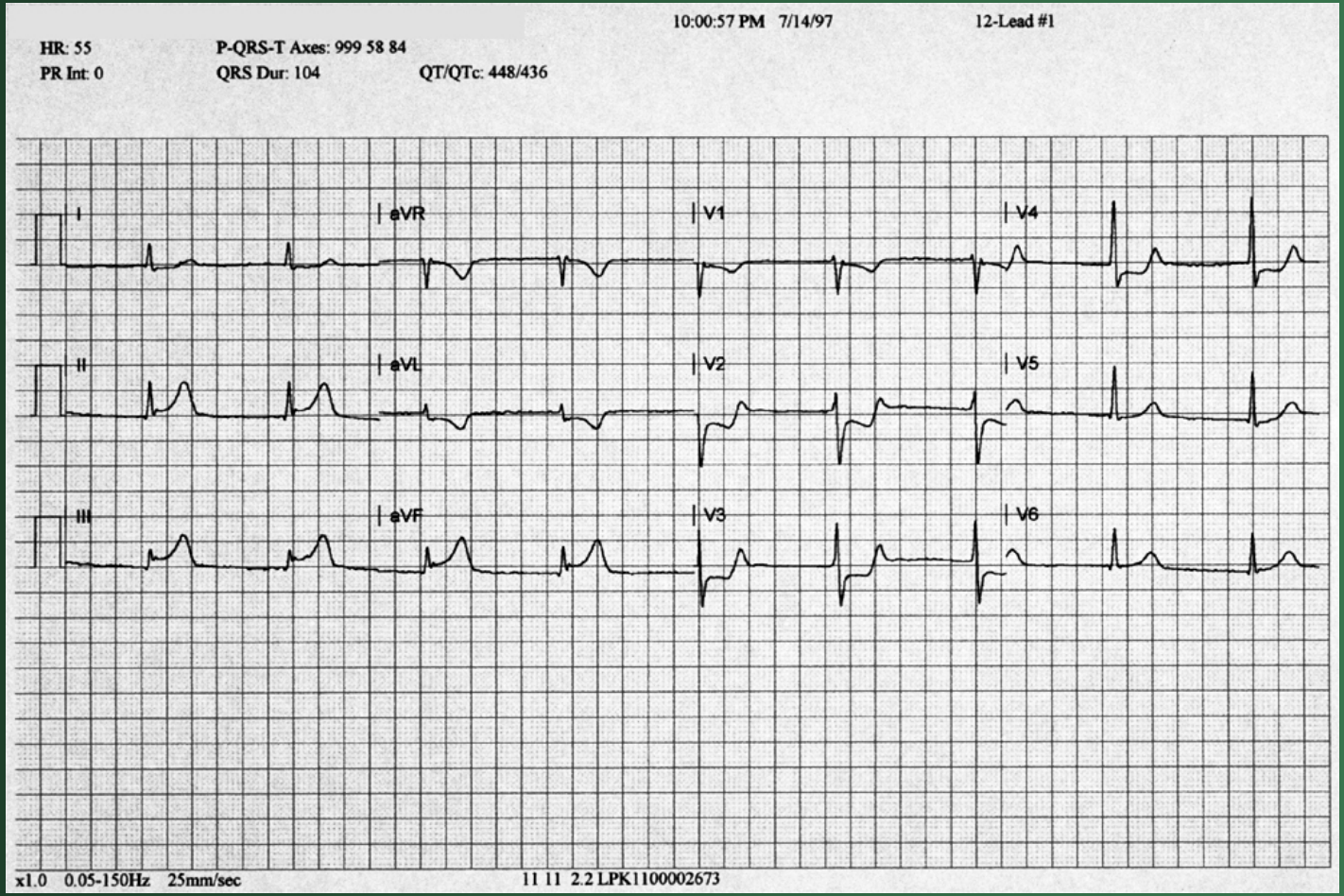
10:00:57 PM 7/14/97
12-Lead #1
HR: 55
PR Int: 0
P-QRS-T Axes: 999 58 84
QRS Dur: 104
QT/QTc: 448/436
I
aVR
V1
V4
II
aVL
V2
V5
III
aVF
V3
V6
x1.0 0.05-150Hz 25mm/sec
11 11 2.2 LPK1100002673

WOULD YOU PLEASE GIVE IT A REST SIR?: MY MONITOR LEADS KEEP CHANGING.
BERRY 96©

Practice

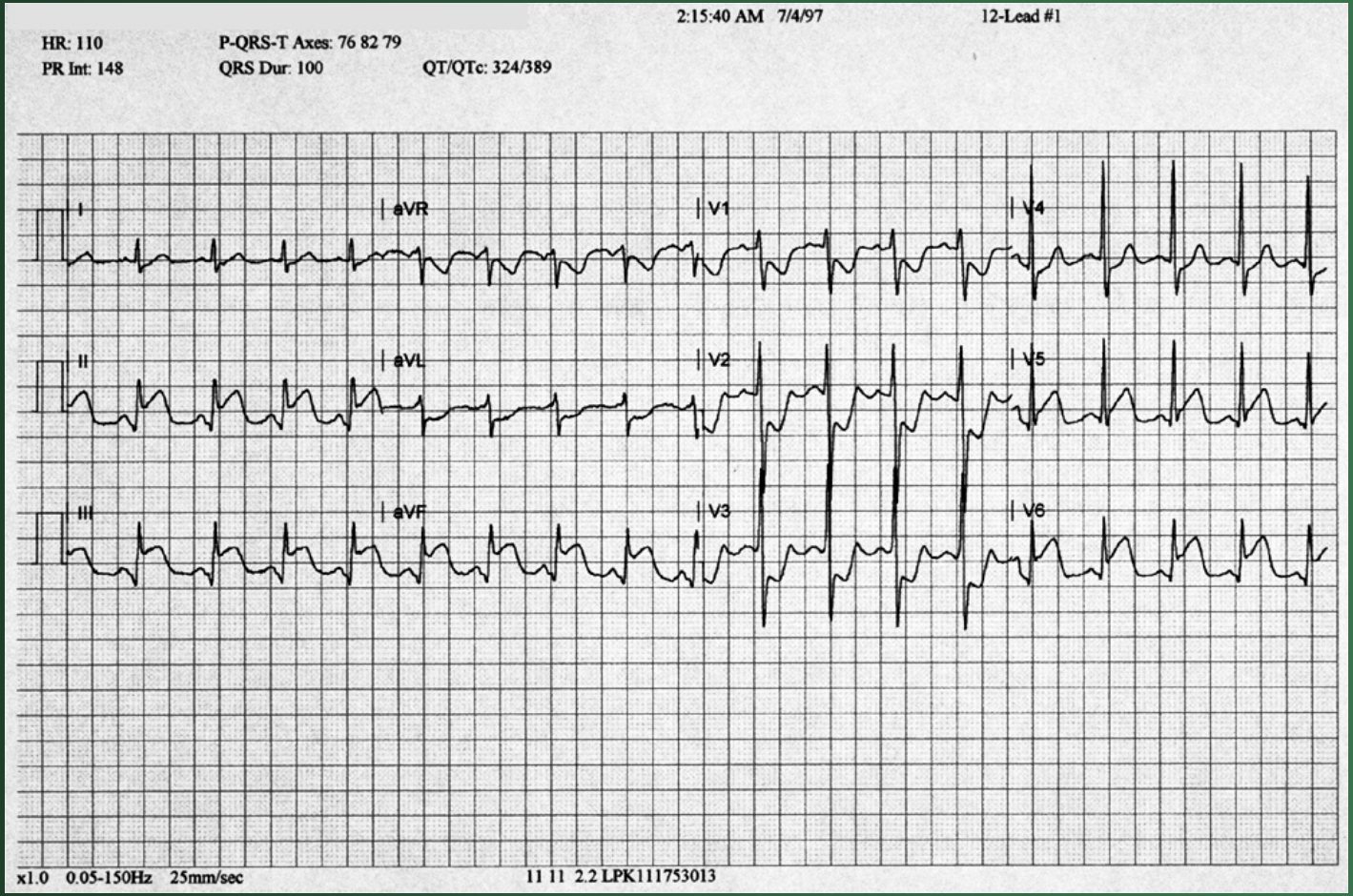
2:15:40 AM 7/4/97
12-Lead #1
HR: 110
PR Int: 148
P-QRS-T Axes: 76 82 79
QRS Dur: 100
QT/QTc: 324/389
I
aVR
V1
V4
II
aVL
V2
V5
III
aVF
V3
V6
x1.0 0.05-150Hz 25mm/sec
11 11 2.2 LPK111753013

Extensive Anterior MI

- Evidence in septal, anterior, and lateral leads
- Often from proximal LCA lesion
- "Widow Maker"
- Complications common!

more practice

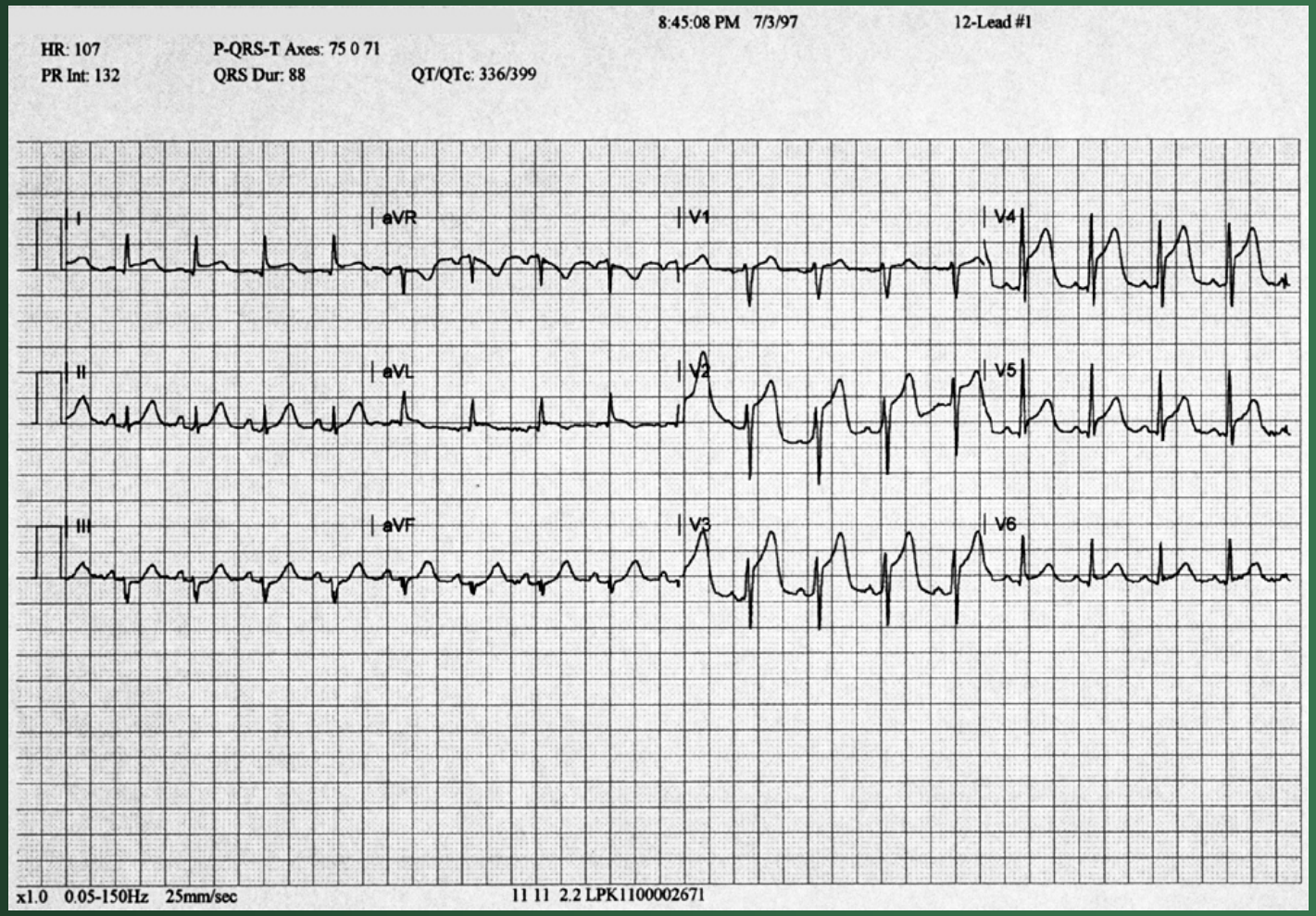

even more practice

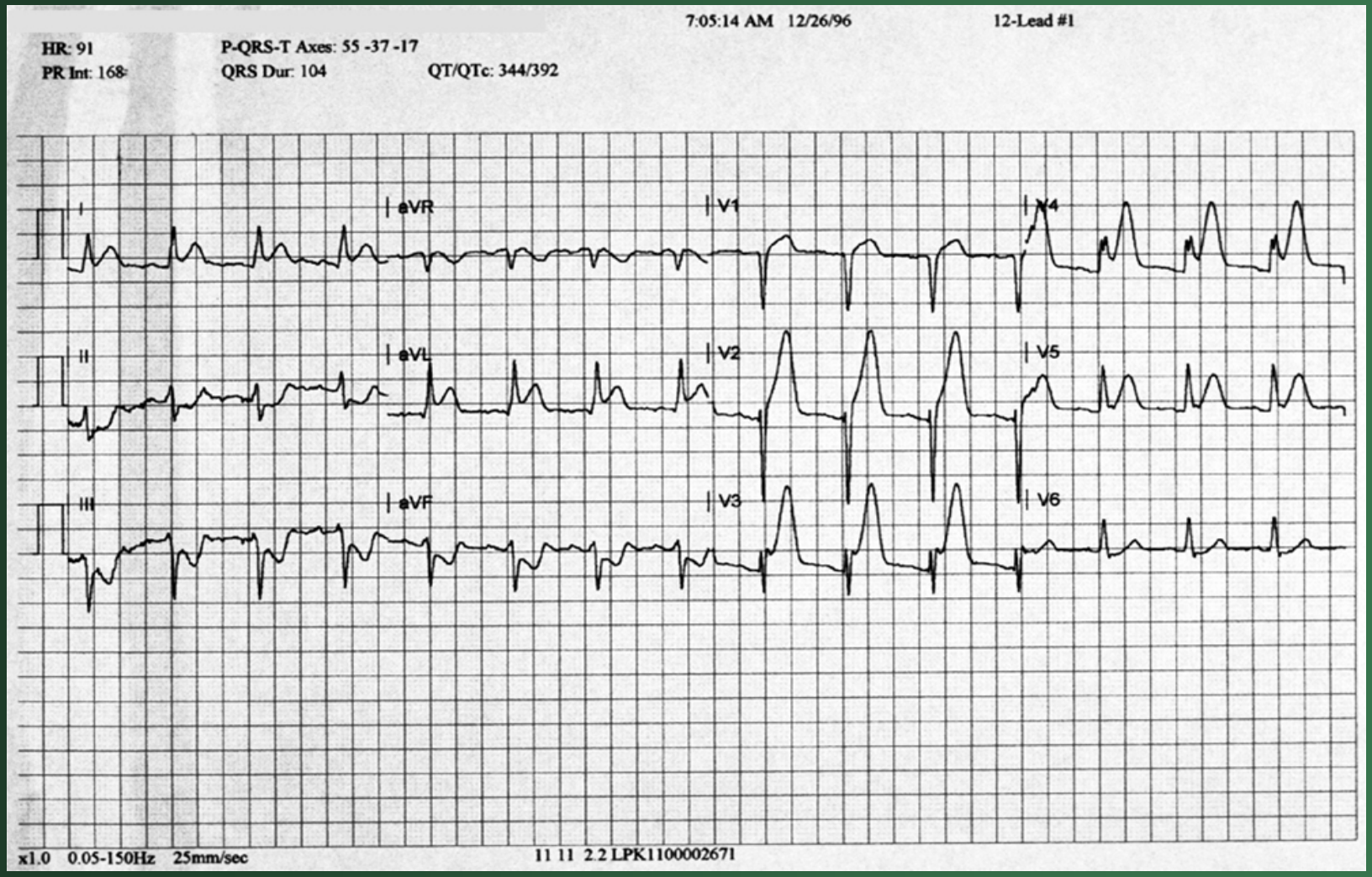

Proximal RCA Occlusion

- Right Ventricular Infarct (RVI)
- 12-lead ECG <u>does not</u> view right ventricle
- Use additional leads
- V4R

Physical Evidence of RVI (triad of RVI)

- Dyspnea with clear lungs
- Jugular vein distension
- Hypotension
  - Relative or absolute

Treatment for RVI

- Use caution with vasodilators
  - Small incremental doses of MS
  - NTG by drip



Fluid for Hypotension

- One to two liters may be required
- “Large bore” lines here

Practice

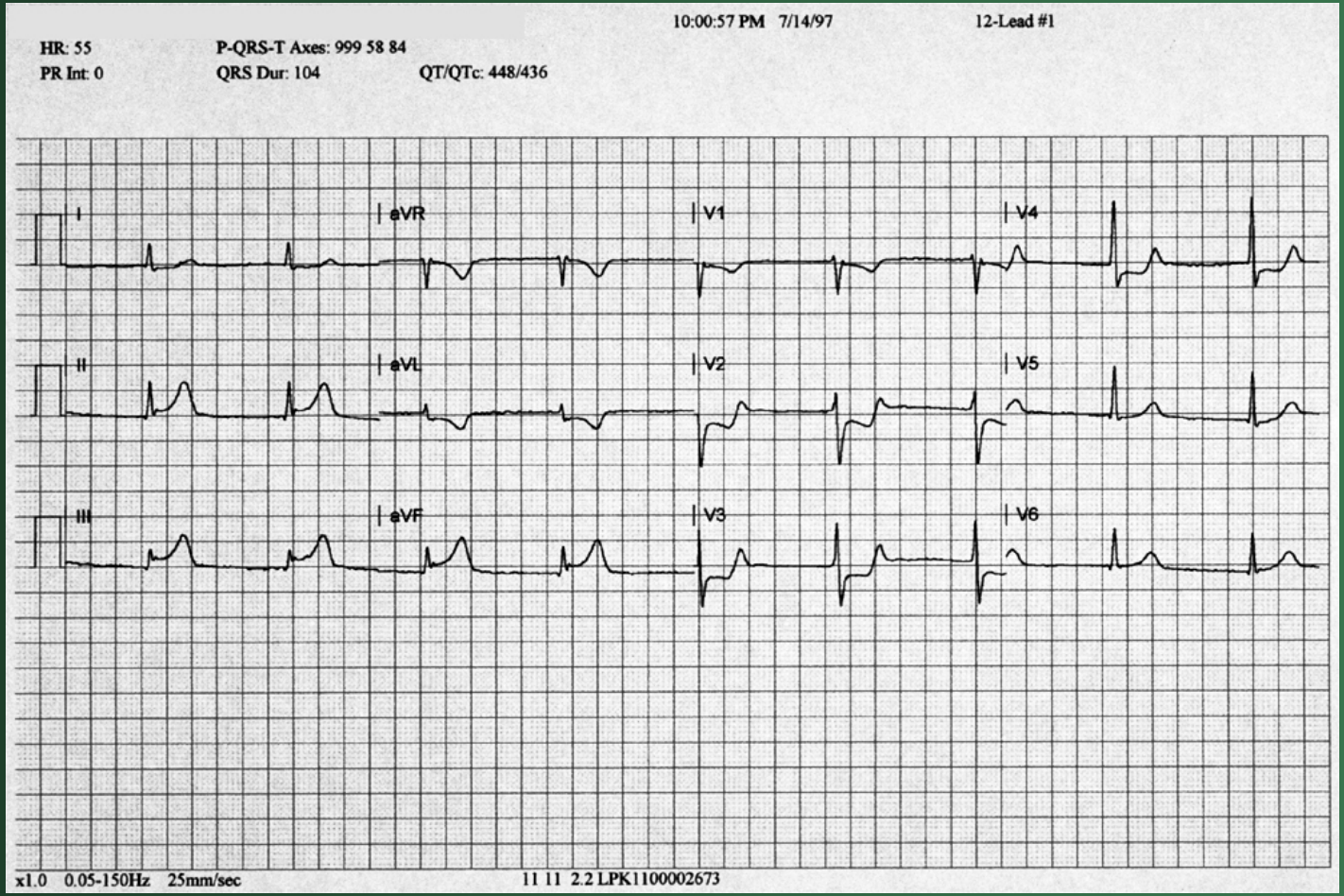
10:00:57 PM 7/14/97
12-Lead #1
HR: 55
PR Int: 0
P-QRS-T Axes: 999 58 84
QRS Dur: 104
QT/QTc: 448/436
I
aVR
V1
V4
II
aVL
V2
V5
III
aVF
V3
V6
x1.0 0.05-150Hz 25mm/sec
11 11 2.2 LPK1100002673

Practice

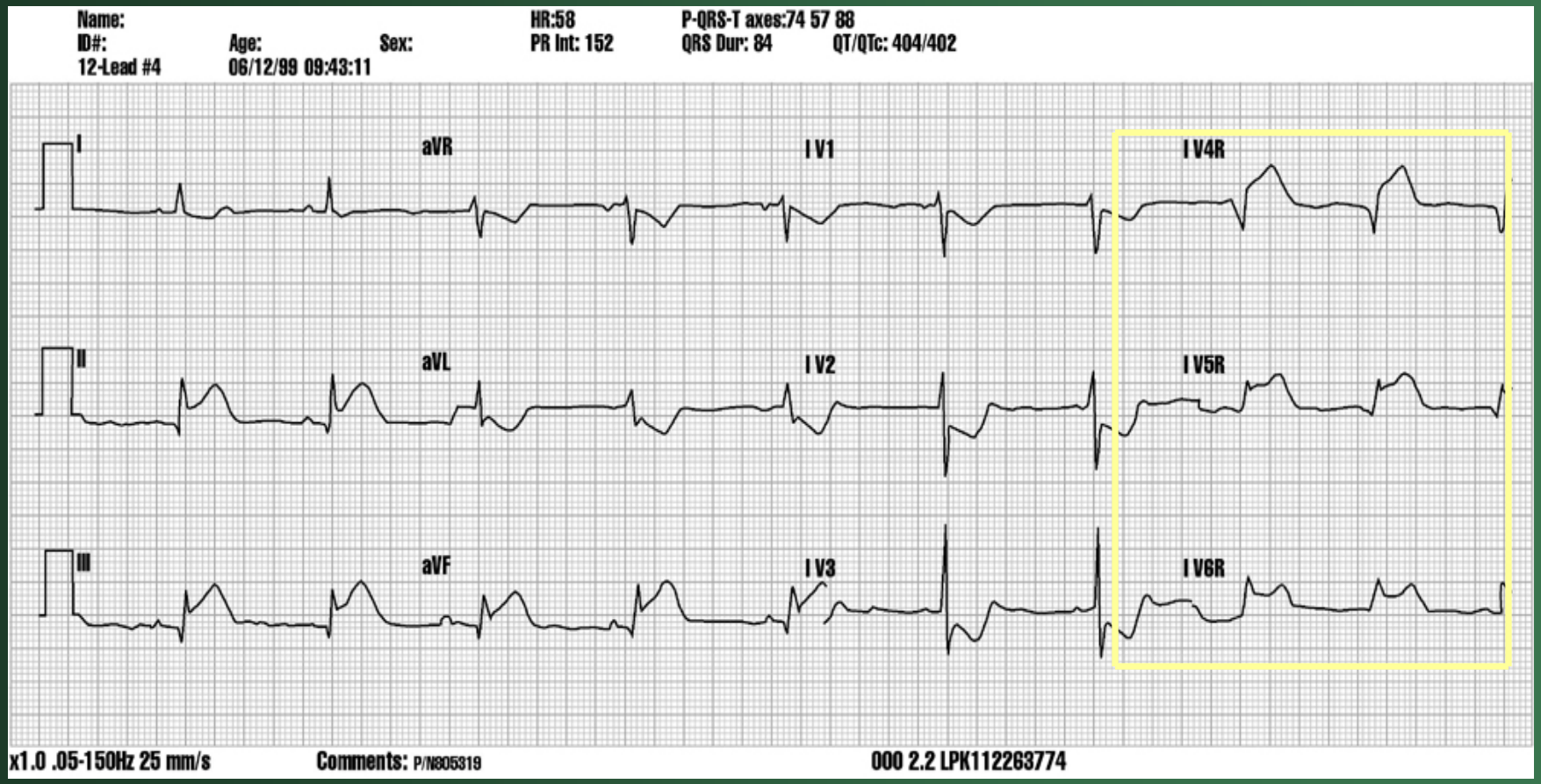
Name:
ID#:
12-Lead #4
Age:
06/12/99 09:43:11
Sex:
HR:58
PR Int: 152
P-QRS-T axes:74 57 88
QRS Dur: 84
QT/QTc: 404/402
I
aVR
I V1
I V4R
II
aVL
I V2
I V5R
III
aVF
I V3
I V6R
x1.0 .05-150Hz 25 mm/s
Comments: P/N805319
000 2.2 LPK112263774

Posterior Wall MI (PWMI)

- Usually an extension of an inferior or lateral MI
- Common with proximal RCA occlusions
- May occur with LCX occlusions

PWMI

- Reciprocal changes
  - V1 - V4
- Indicative changes
  - V7, V8, V9

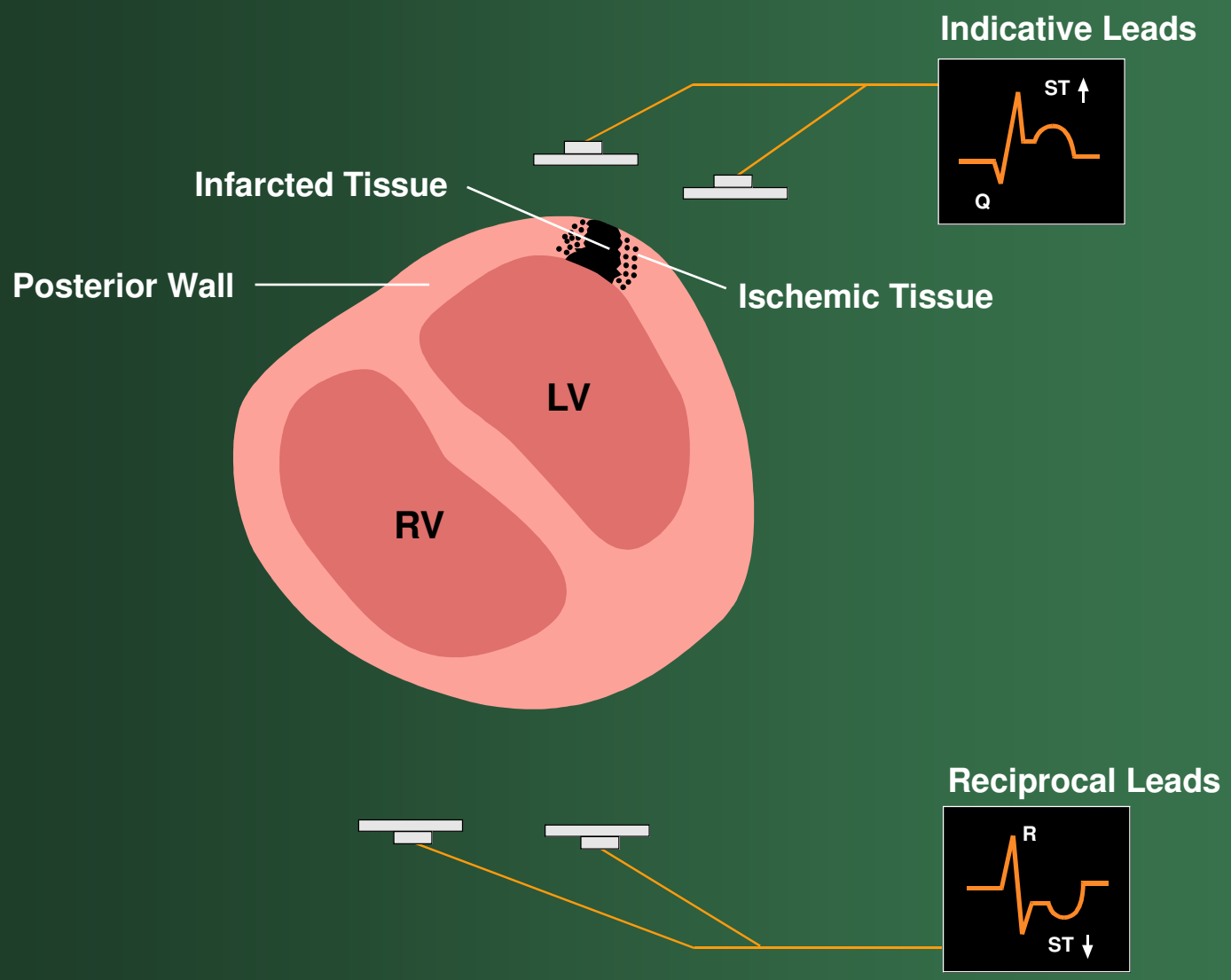
Indicative Leads
ST
Q
Infarcted Tissue
Posterior Wall
Ischemic Tissue
LV
RV
Reciprocal Leads
R
ST

Posterior Leads

- V7
  - Posterior axillary line
  - Level with V6
- V8
  - Mid-scapular line
  - Level with V6
- V9
  - Left para-vertebral
  - Level with V6

Practice

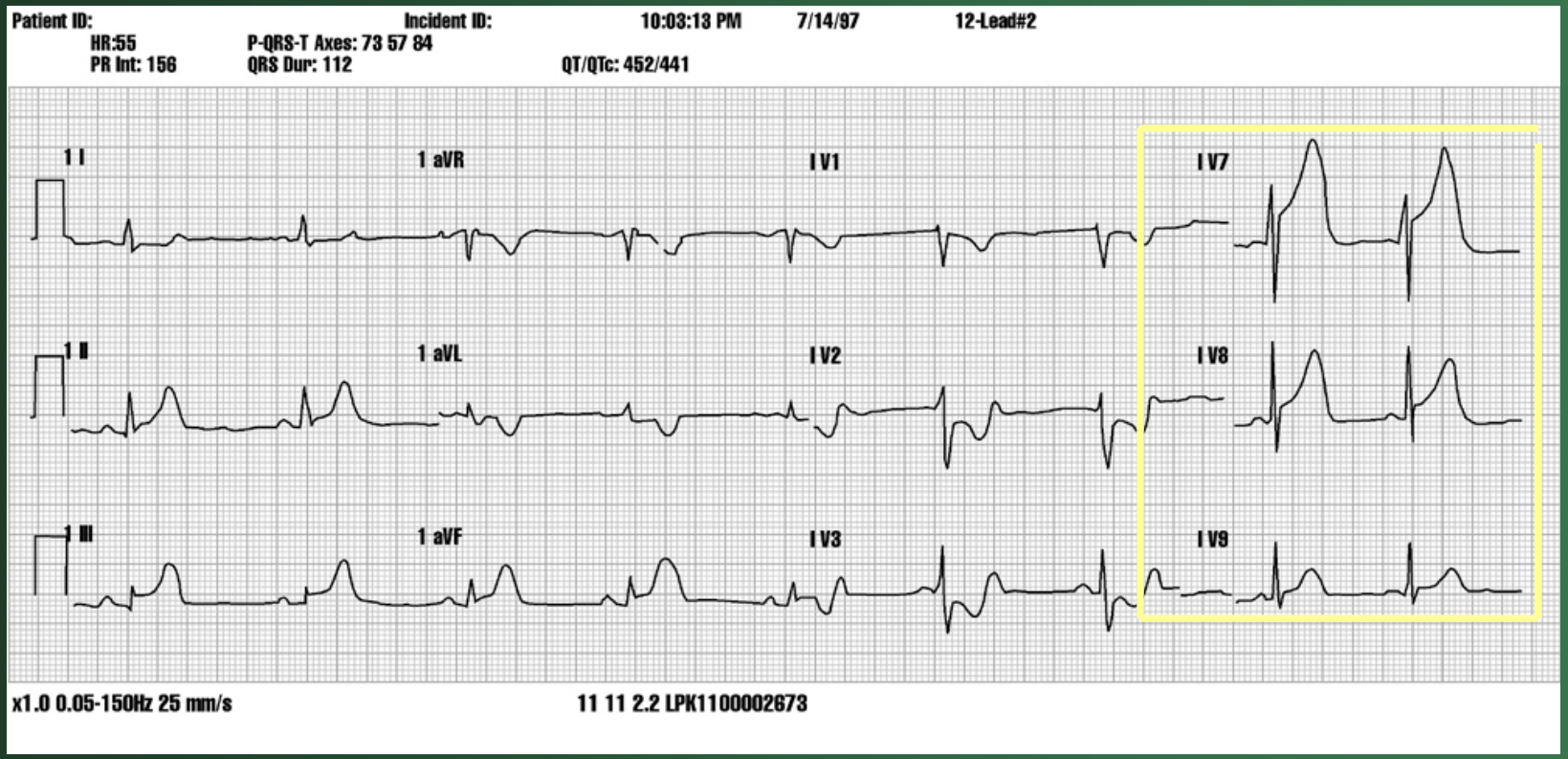
Patient ID:
Incident ID:
10:03:13 PM
7/14/97
12-Lead#2
HR:55
P-QRS-T Axes: 73 57 84
PR Int: 156
QRS Dur: 112
QT/QTc: 452/441
1 I
1 aVR
I V1
I V7
1 II
1 aVL
I V2
I V8
1 III
1 aVF
I V3
I V9
x1.0 0.05-150Hz 25 mm/s
11 11 2.2 LPK1100002673

Pulmonary Embolus

- Typical presentation in lg. PE:
  - Tachypnea, tachycardia, dyspnea, CP, anxiety, low Sao2, low grade fever
  - Predisposing factors
  - 12 lead: S1, Q3, T3
  - ST, RBBB, low amplitude

ECG findings
S1 Q3 T3

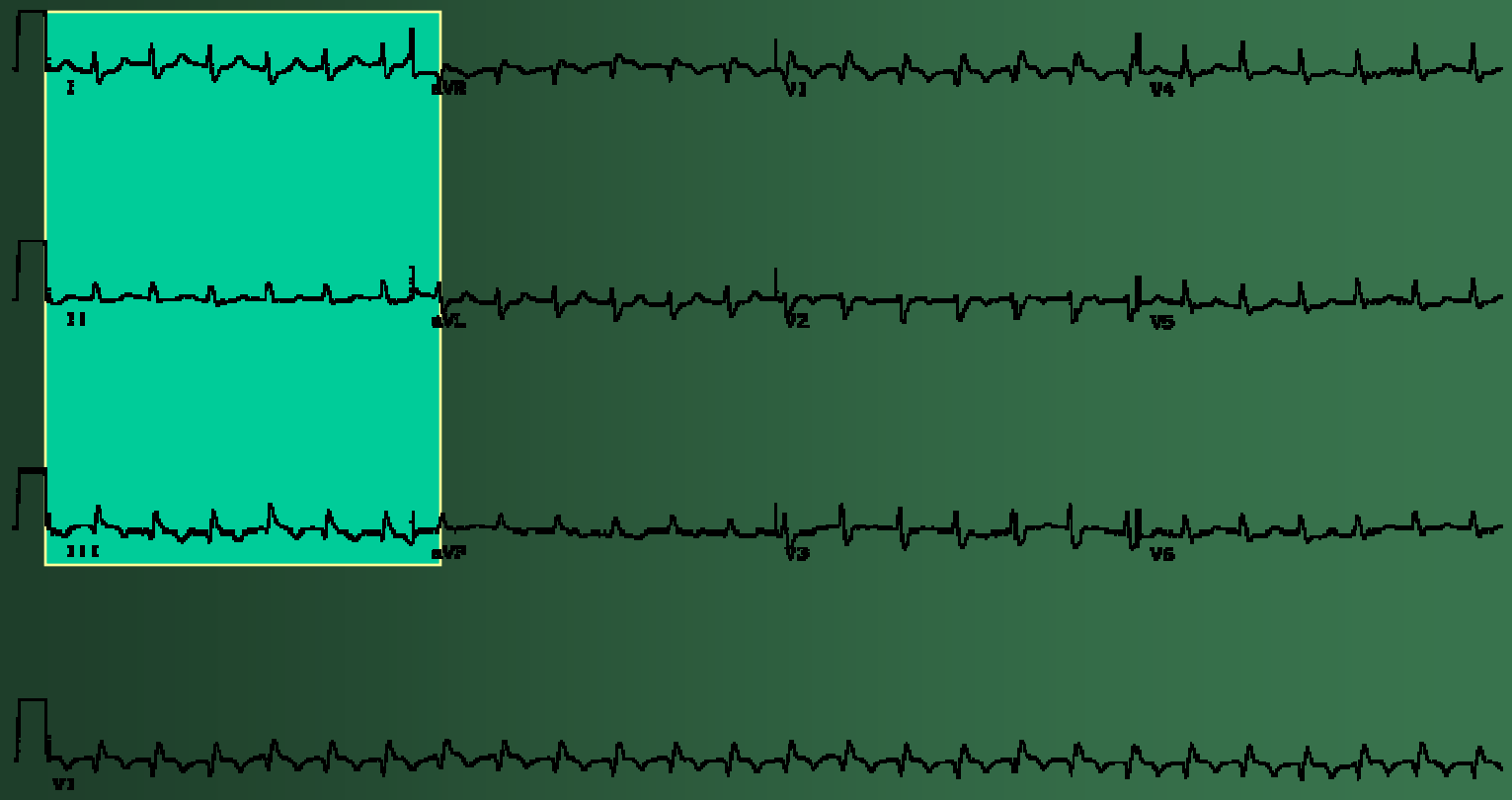

AXIS

- Axis is the direction of travel of the electrical impulse
- LLQ “normal” 60 degrees LII
- Impulses traveling toward a positive electrode inscribes a + deflection

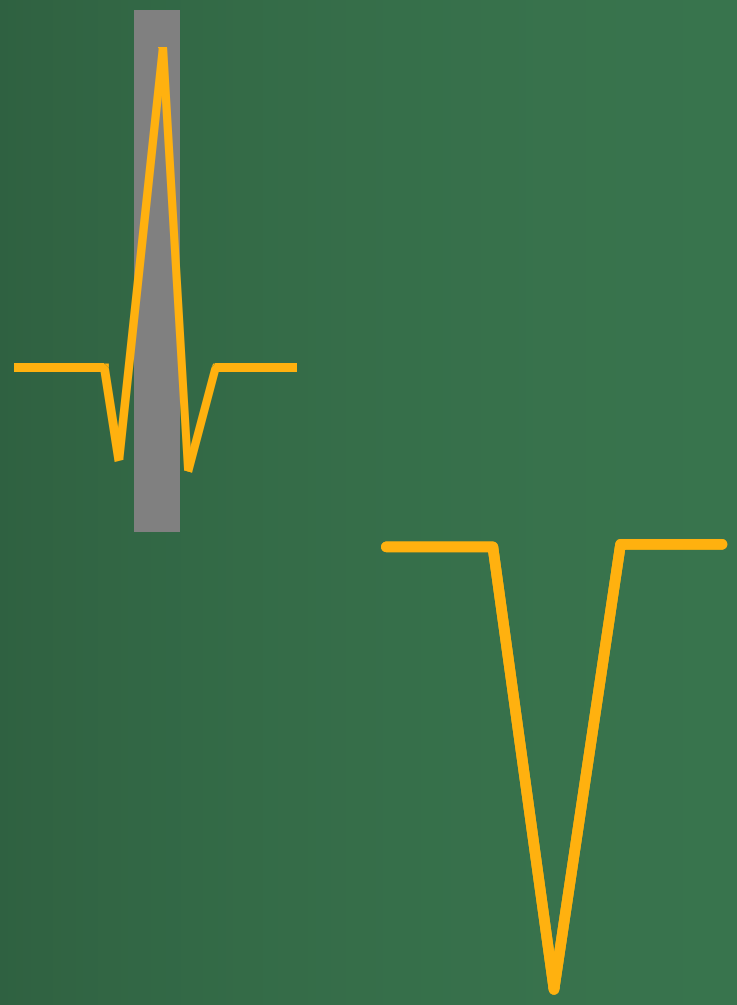

Limb Leads

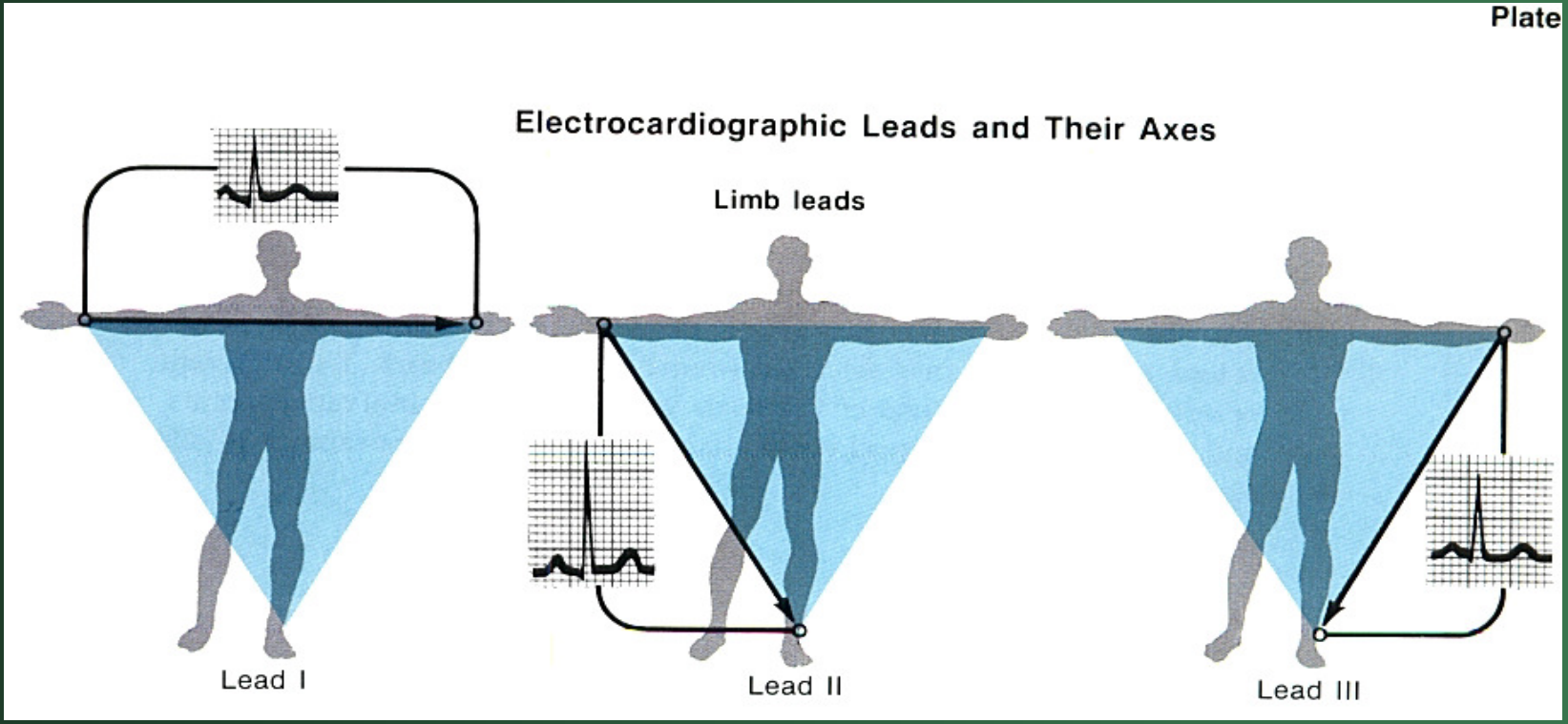
Plate
Electrocardiographic Leads and Their Axes
Limb leads
Lead I
Lead II
Lead III

Hex-axial reference

- Know 0 degrees is at the L arm
- 180 degrees is at the R arm
- Easiest to break down into “4 quadrants”

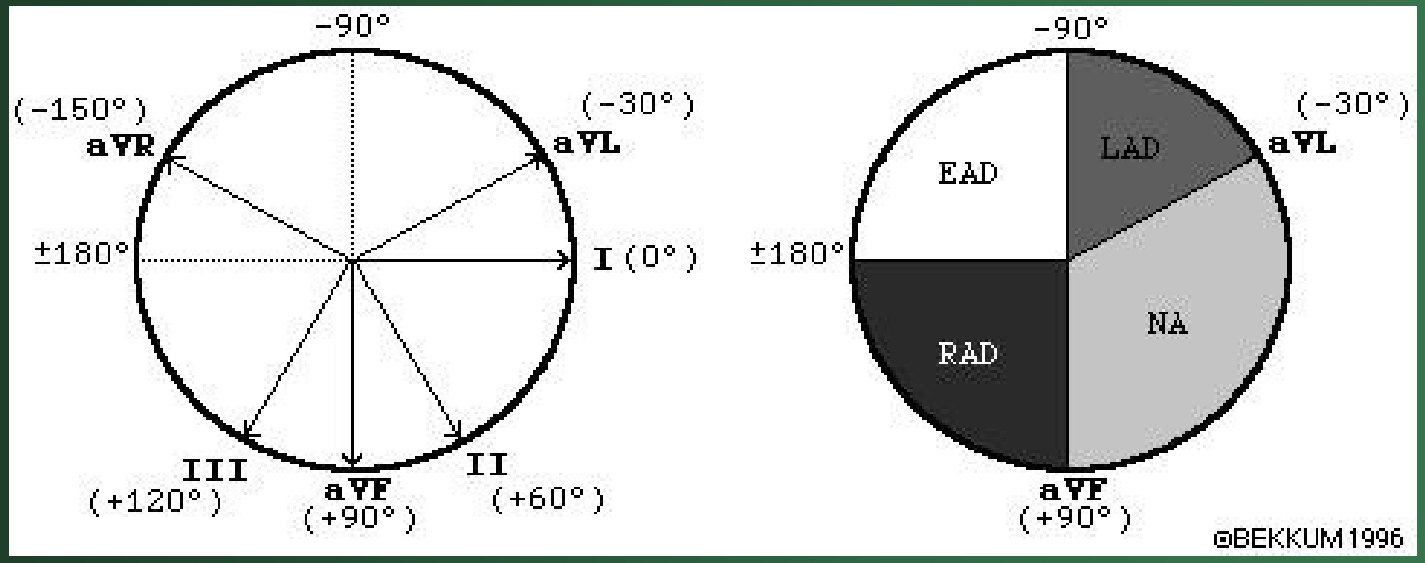

VT

- Advanced age
- Width
- regular
- CAD
- AV dissociation (p waves)
- Fusion capture beats
- Extreme axis
- Upright complex in V1
- Negative complex in V6
- Concordance

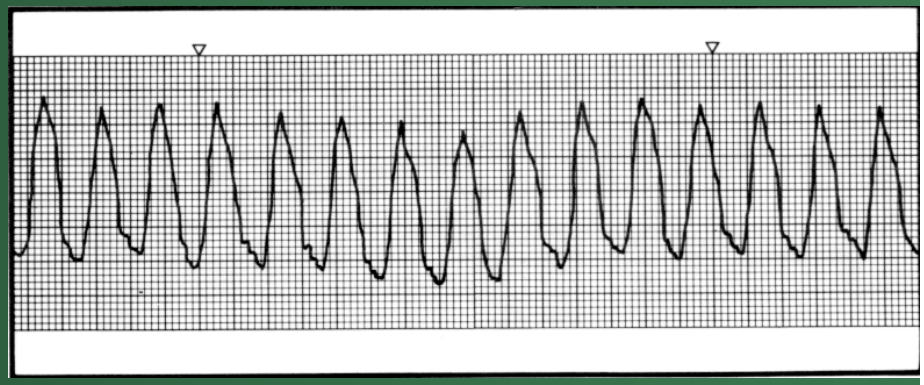

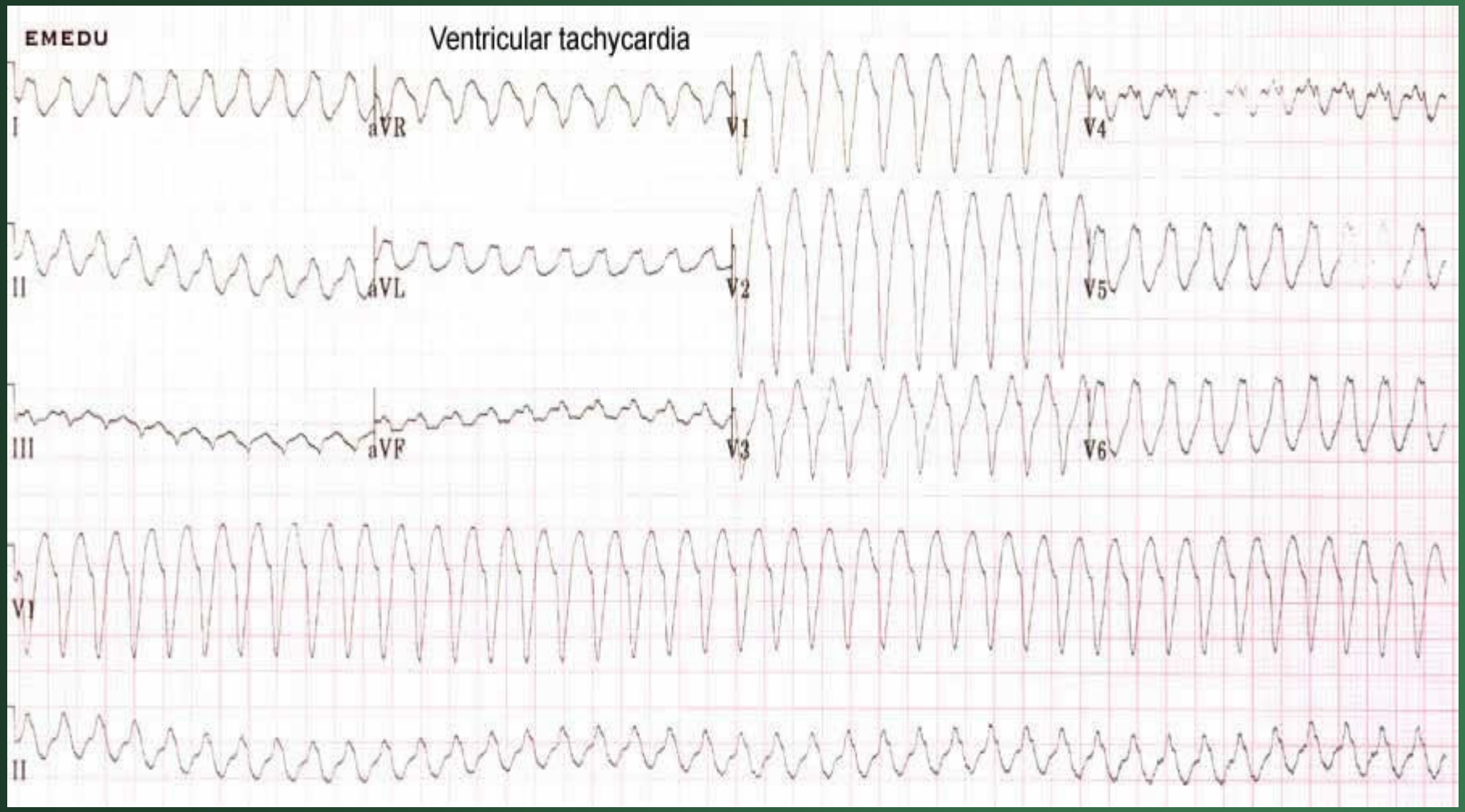
EMEDU
Ventricular tachycardia
I
aVR
V1
V4
II
aVL
V2
V5
III
aVF
V3
V6
V1
II

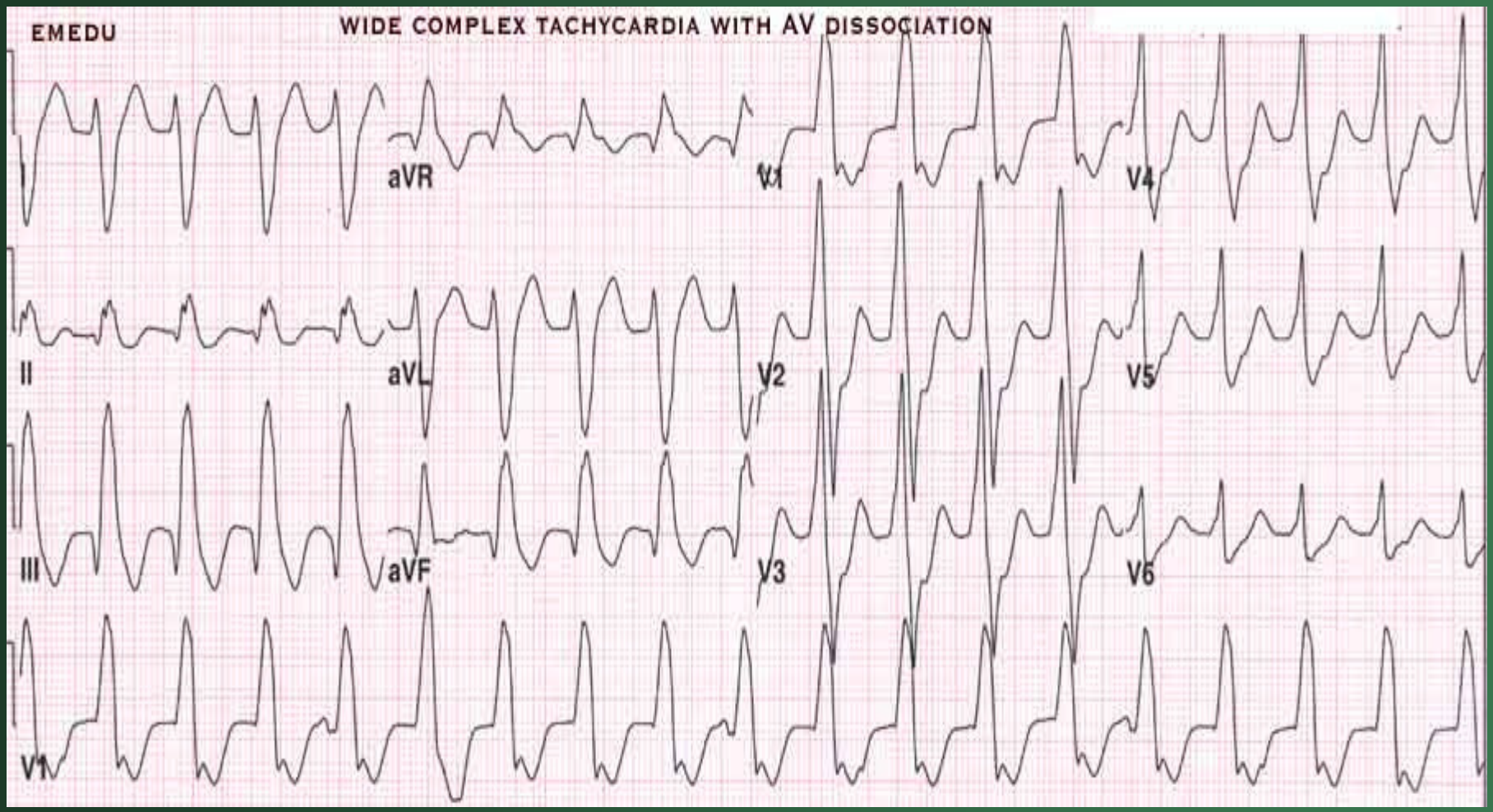
EMEDU
WIDE COMPLEX TACHYCARDIA WITH AV DISSOCIATION
I
aVR
V1
V4
II
aVL
V2
V5
III
aVF
V3
V6
V1

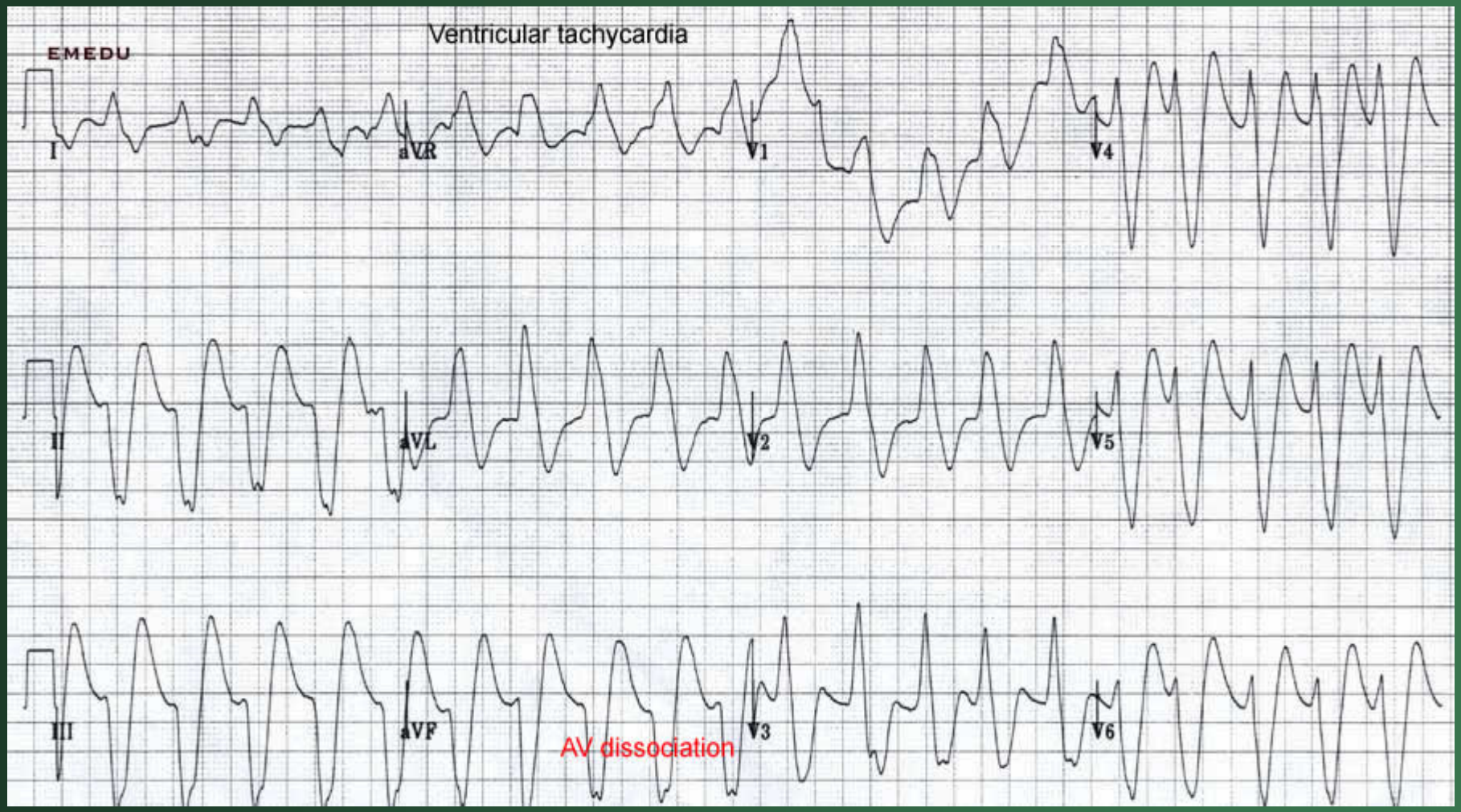
Ventricular tachycardia
EMEDU
I
aVR
V1
V4
II
aVL
V2
V5
III
aVF
V3
V6
AV dissociation

. SUPRAVENTRICULAR TACHYCARDIA, RATE = 205
. SUPERIOR AXIS
. INCOMPLETE RIGHT BUNDLE BRANCH BLOCK
. ANN WITH ST-T ABNORMALITIES
. INFERIOR INFARCT
. NONSPECIFIC LATERAL ST DEPRESSION
. T4,V5,V6 NOT USED FOR MORPHOLOGY ANALYSIS
-ABNORMAL ECG-
RATE 205
PR 140
QRSD 117
QT 251
QTC 403
--AXIS--
P 80
QRS 288
T 82
HORIZONTAL
VERTICAL
Emergency Department
PRELIMINARY. MD must review.
HP507
I
aVR
V1
V4
II
aVL
V2
V5
III
aVF
V3
V6
RHYTHM STRIP: I)
25 mm/sec; 1 cm/mV
LOC 00000-0000
F ~ 40

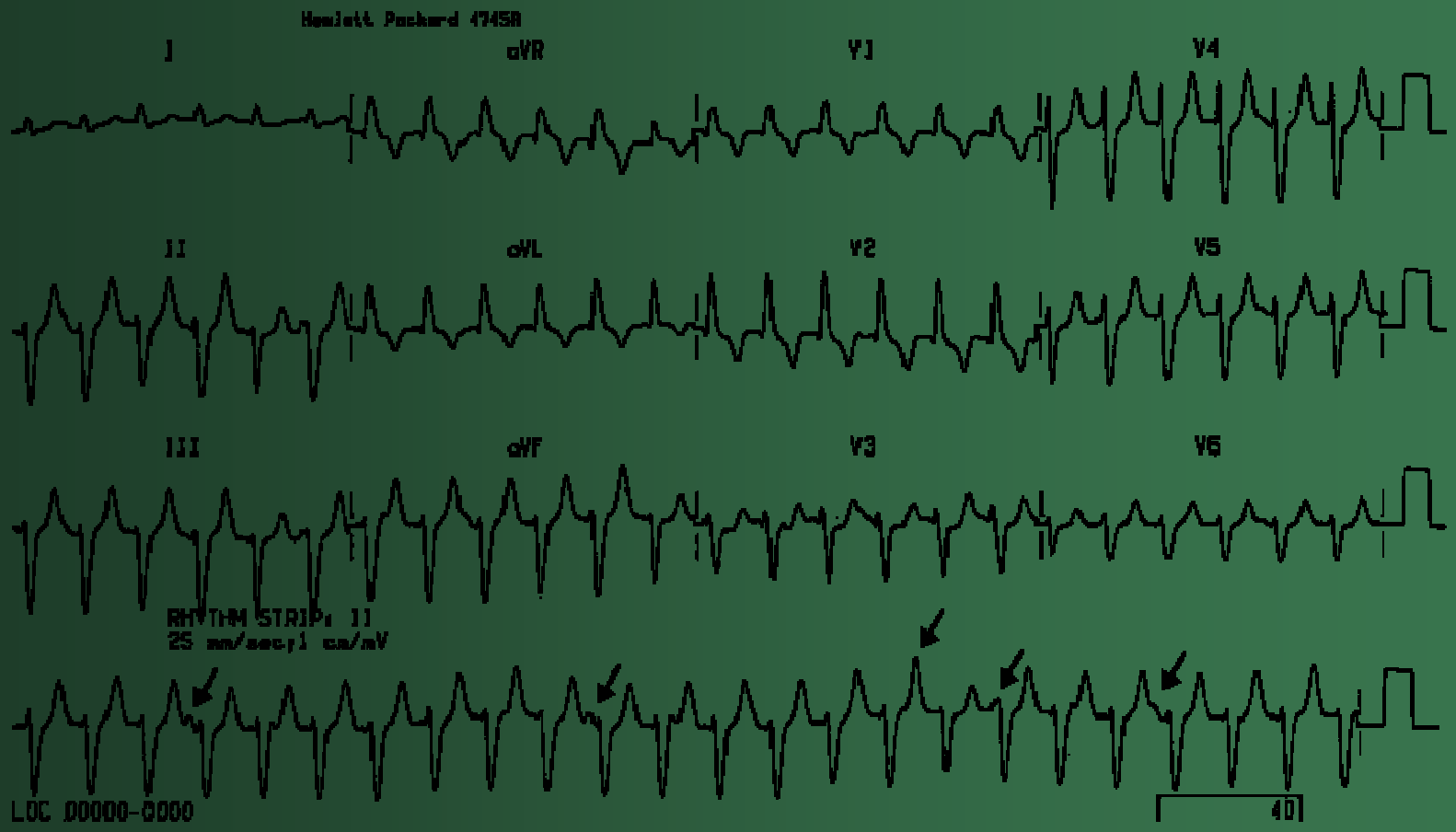
Hewlett Packard 4745A
I
aVR
V1
V4
II
aVL
V2
V5
III
aVF
V3
V6
RHYTHM STRIP: II
25 mm/sec;1 cm/mV
LOC 00000-0000
40

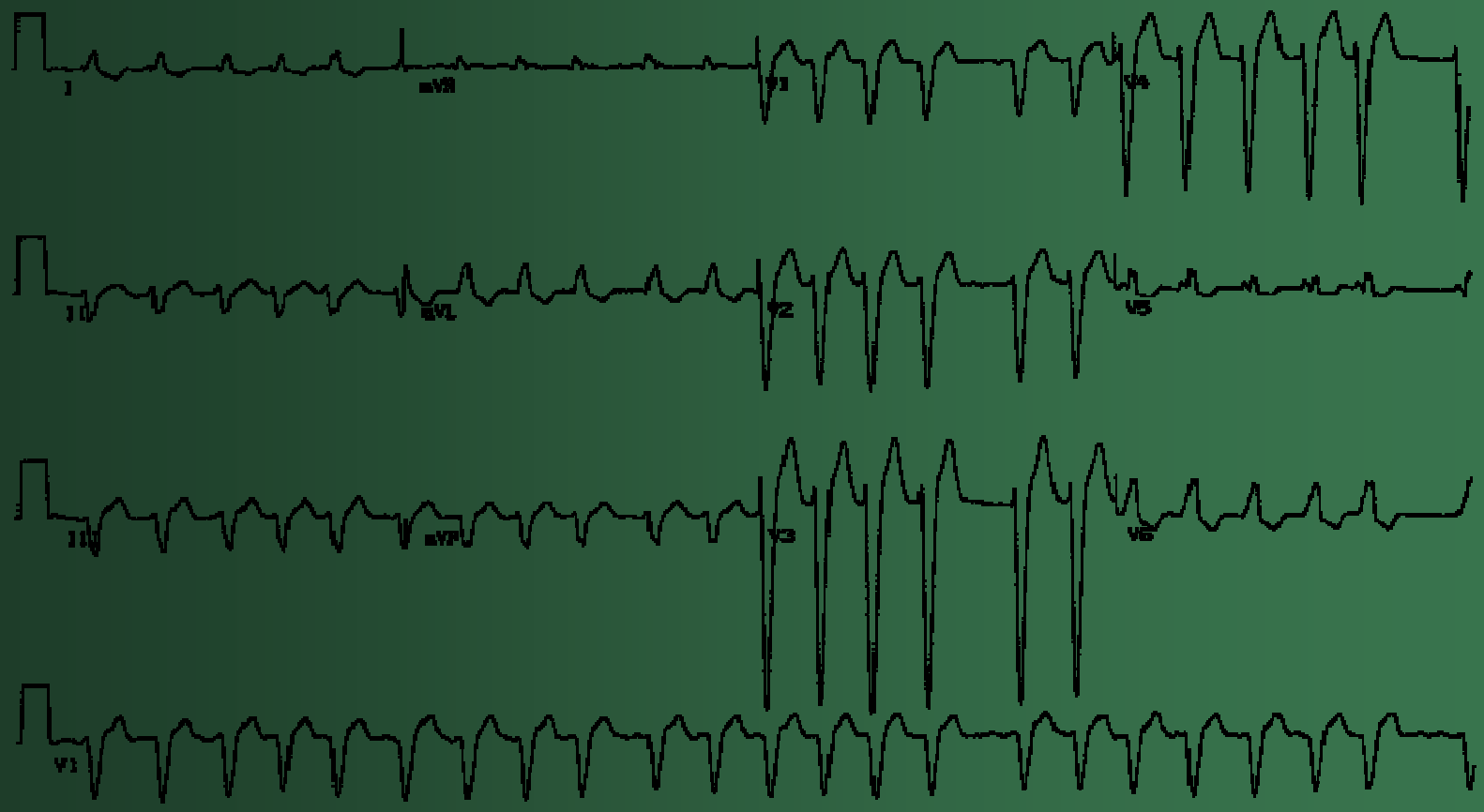
I
aVR
V1
V4
II
aVL
V2
V5
III
aVF
V3
V6
V1

?

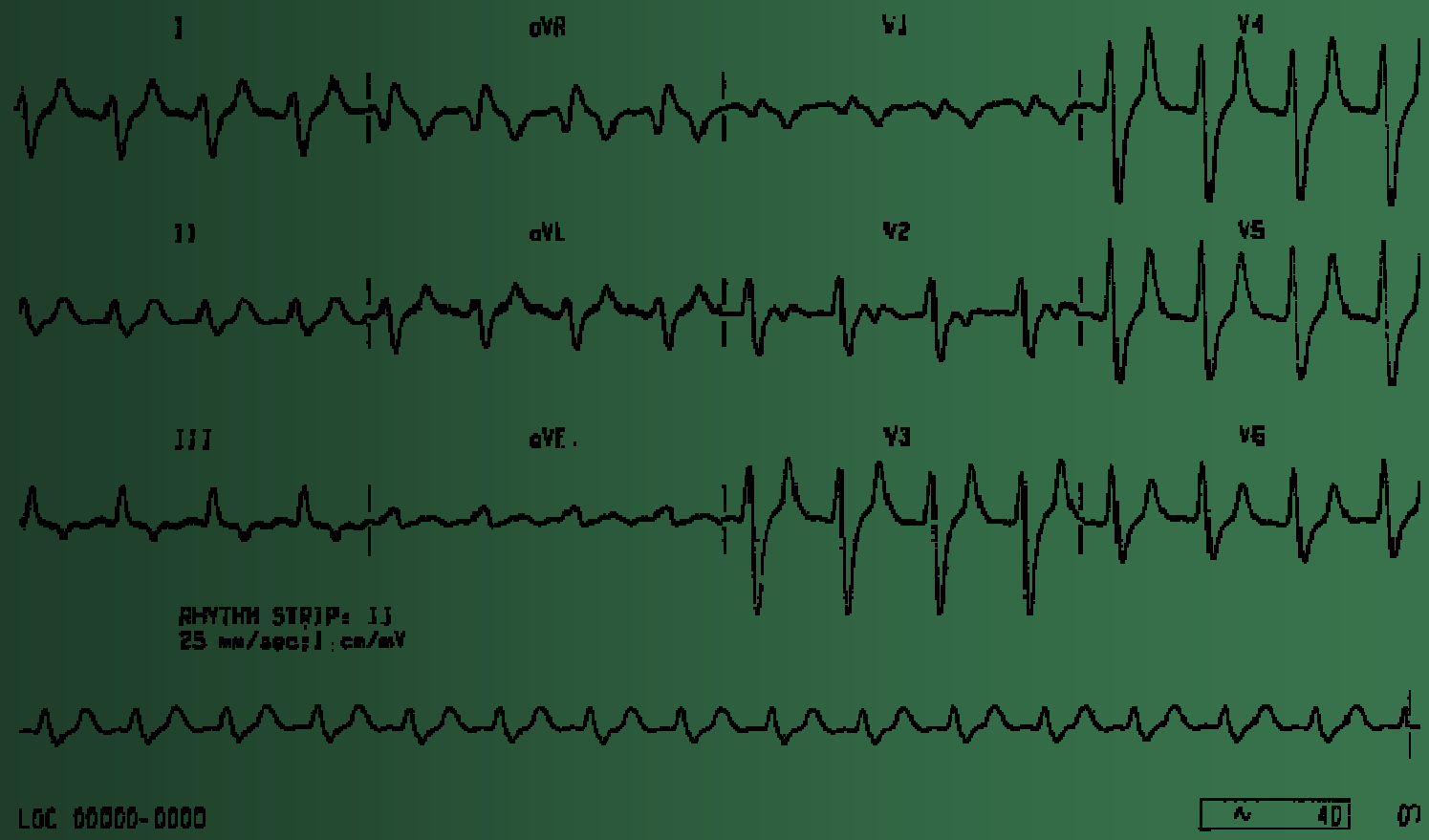
I
aVR
V1
V4
II
aVL
V2
V5
III
aVF
V3
V6
RHYTHM STRIP: II
25 mm/sec;1 cm/mV
LOC 00000-0000
40

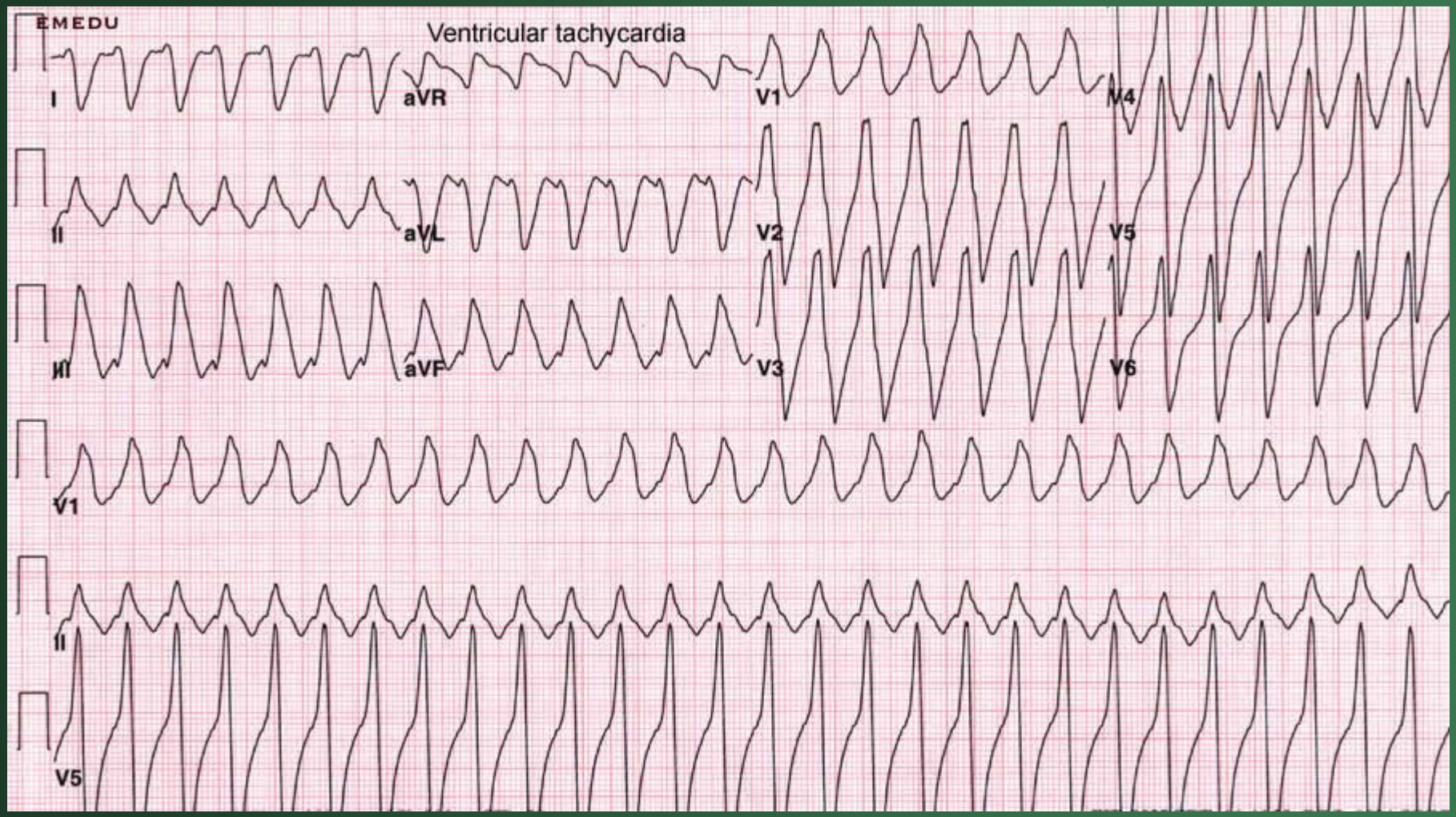
EMEDU
Ventricular tachycardia
I
aVR
V1
V4
II
aVL
V2
V5
III
aVF
V3
V6
V1
II
V5

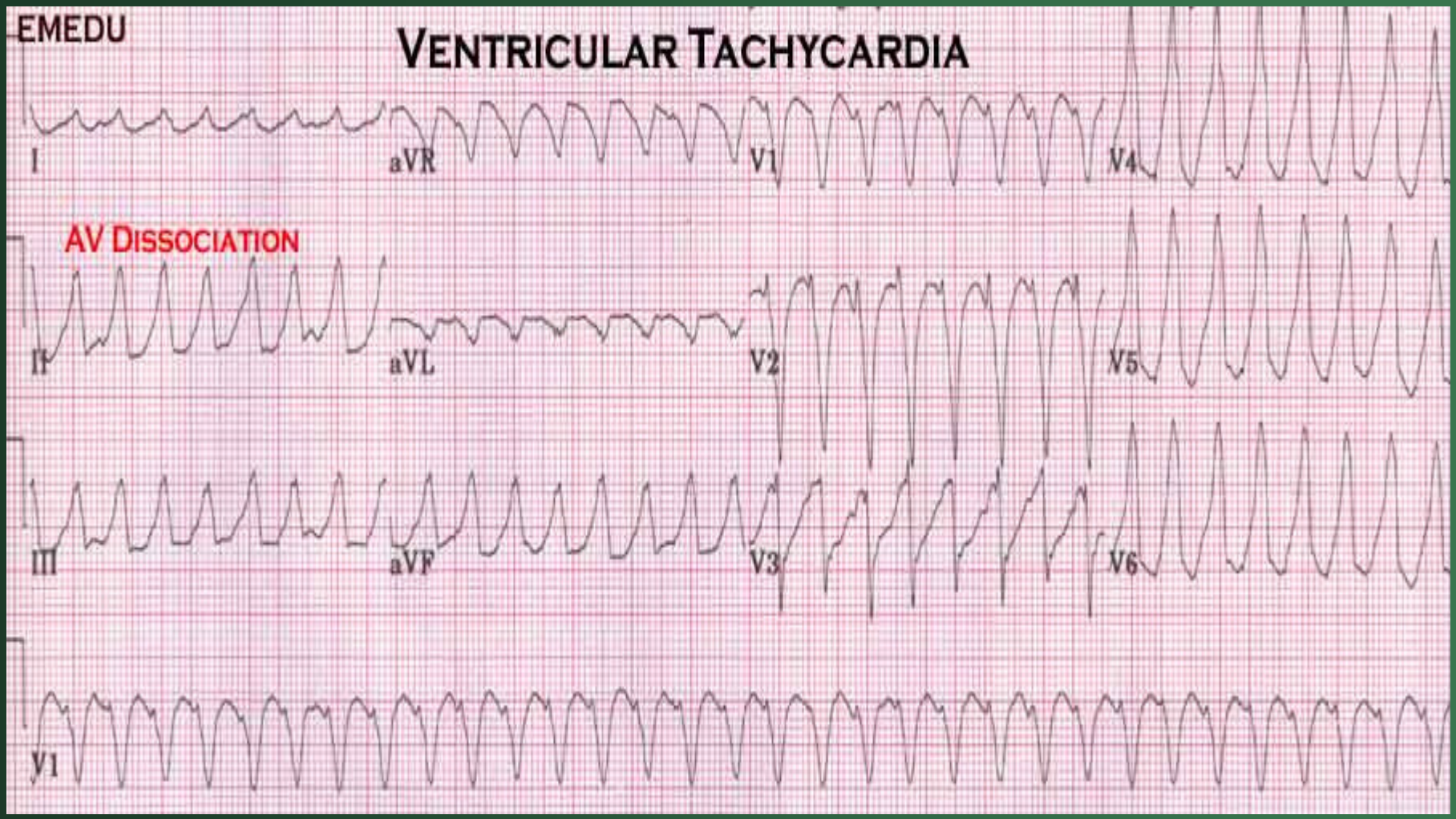
EMEDU
VENTRICULAR TACHYCARDIA
AV DISSOCIATION
I
aVR
V1
V4
II
aVL
V2
V5
III
aVF
V3
V6
V1

?

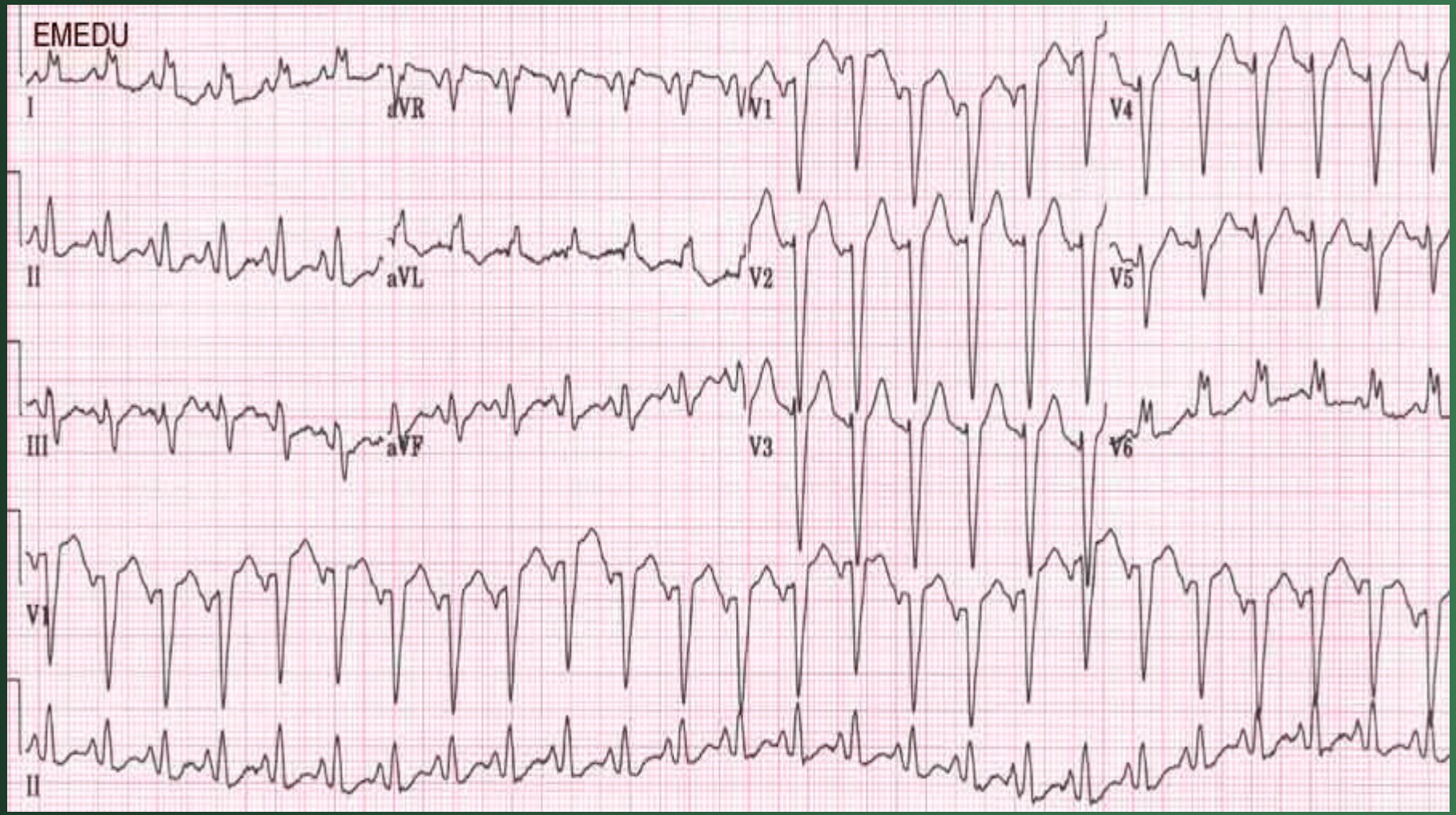
EMEDU
I
aVR
V1
V4
II
aVL
V2
V5
III
aVF
V3
V6
V1
II

SVT

- Regular
- Narrow
- Younger pt
- Faster
- Normal R wave progression

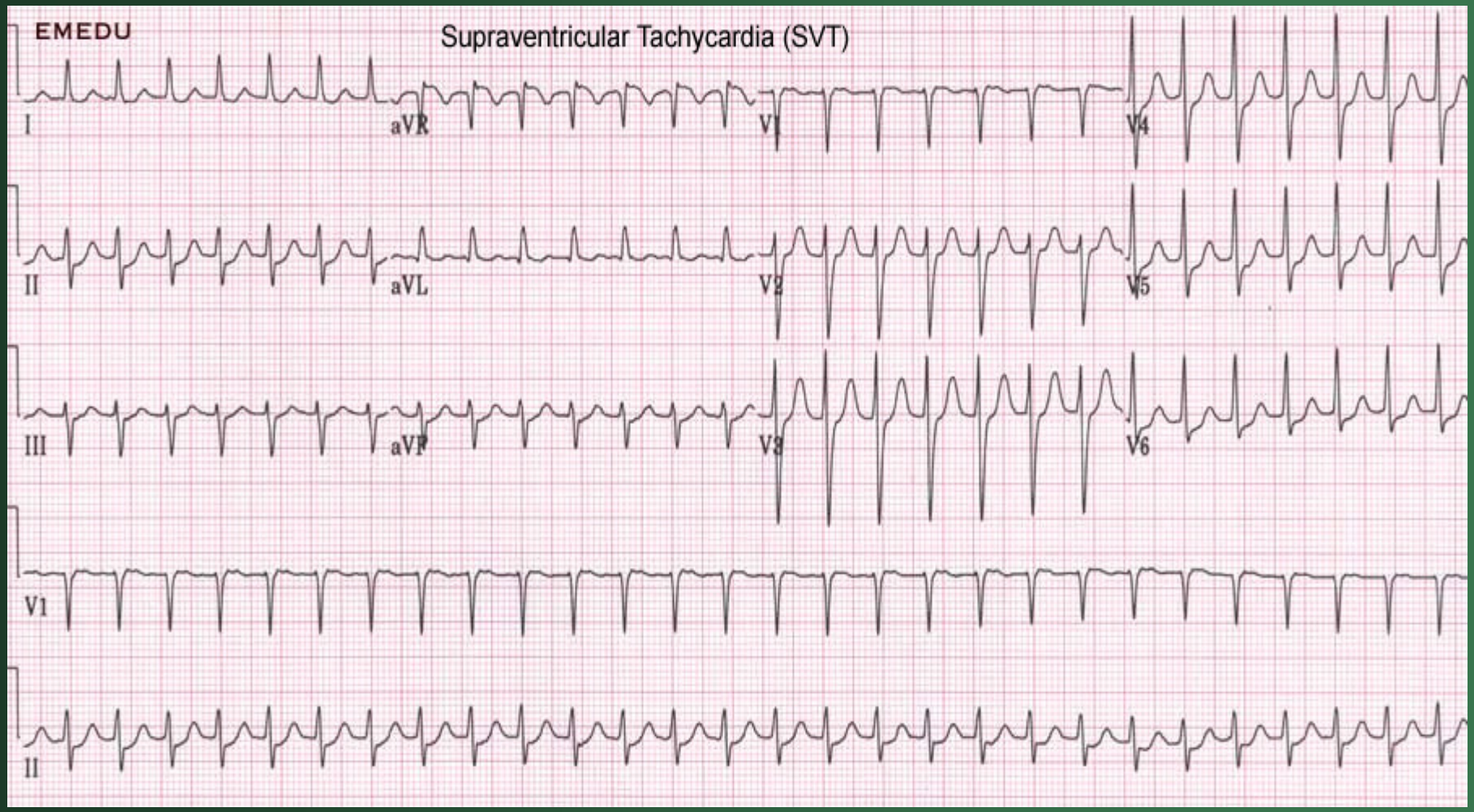
EMEDU
Supraventricular Tachycardia (SVT)
I
aVR
V1
V4
II
aVL
V2
V5
III
aVF
V3
V6
V1
II

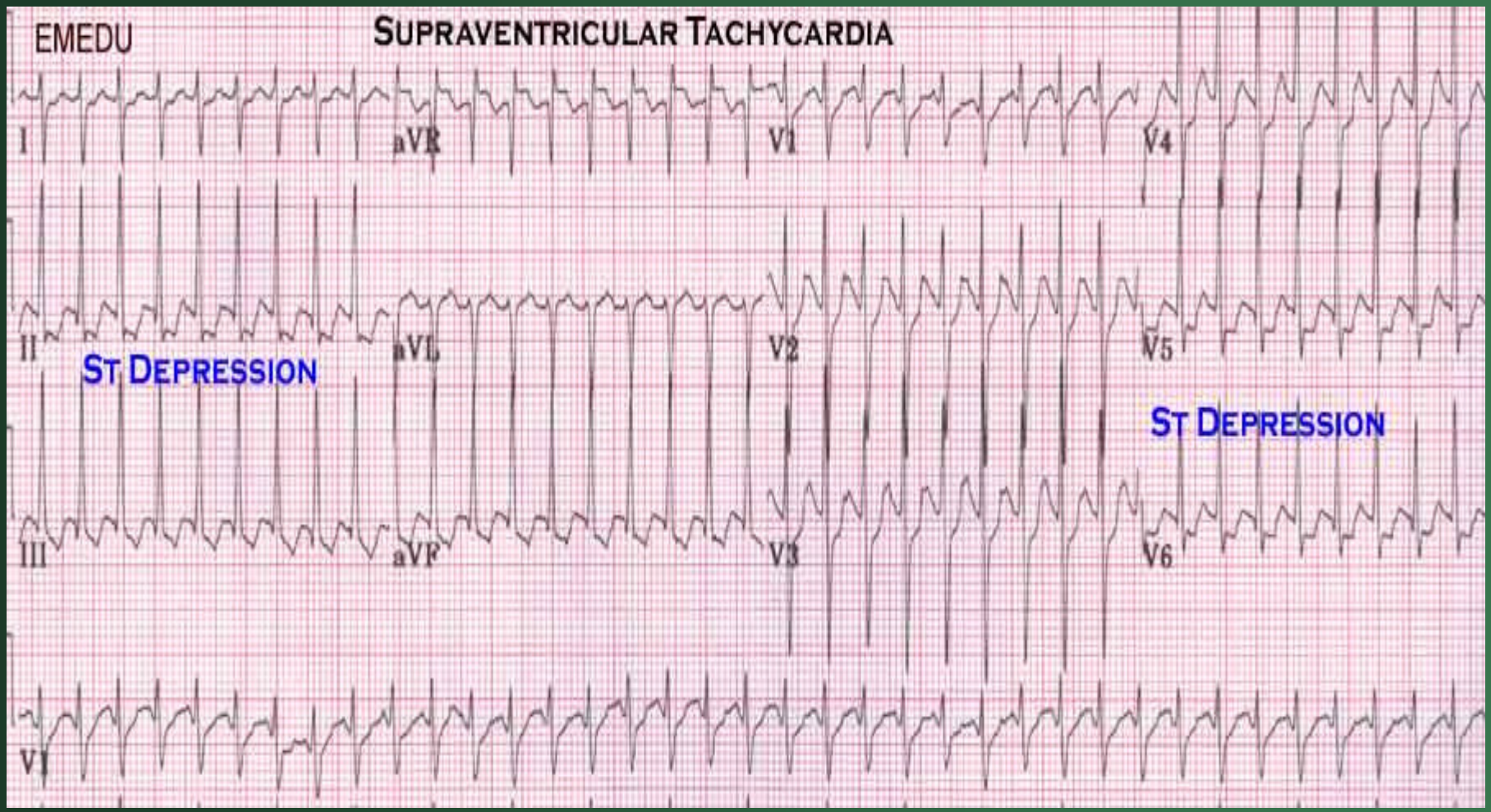
EMEDU
SUPRAVENTRICULAR TACHYCARDIA
I
aVR
V1
V4
II
aVL
V2
V5
III
aVF
V3
V6
VI
ST DEPRESSION
ST DEPRESSION

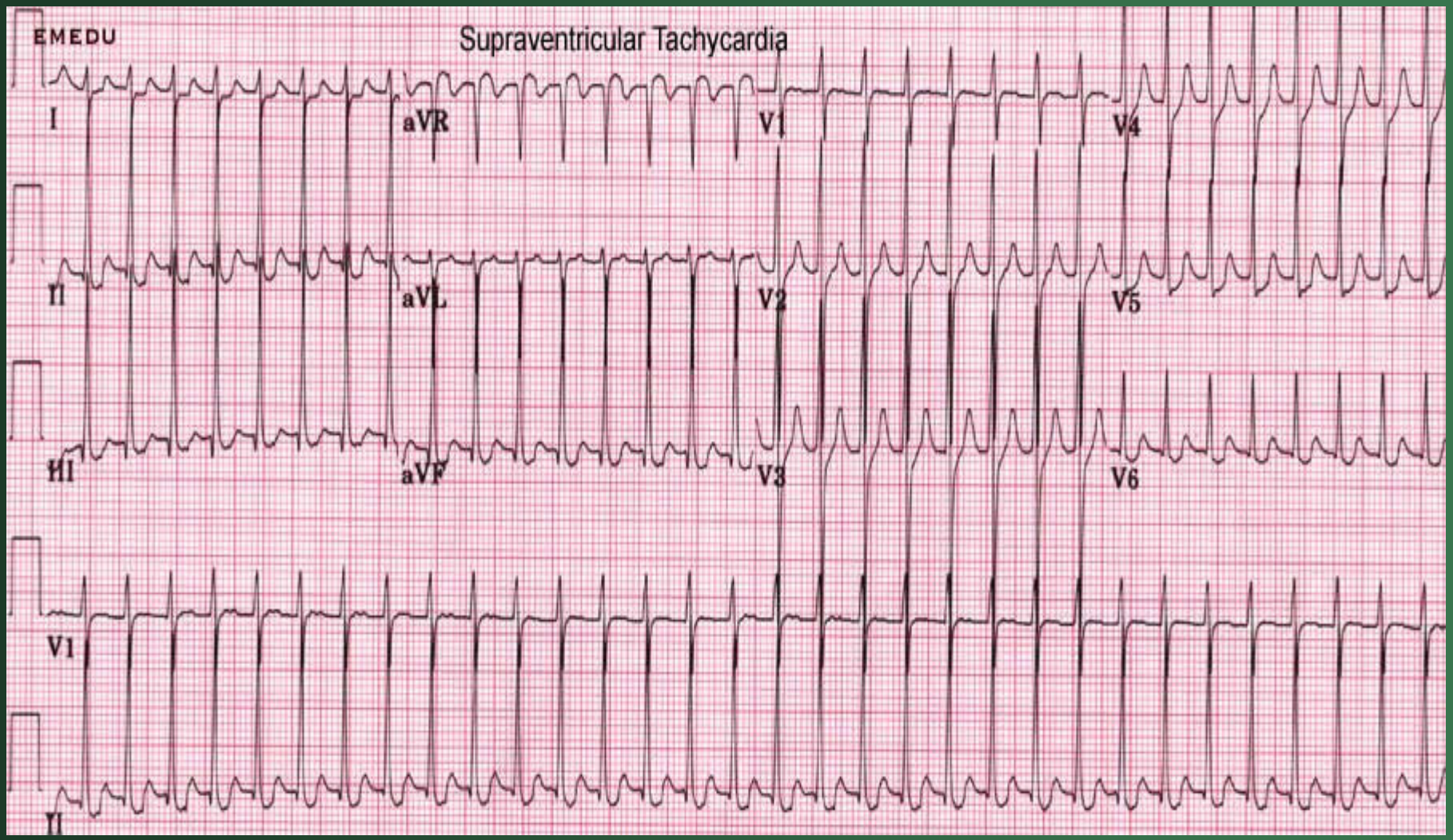
EMEDU
Supraventricular Tachycardia
I
aVR
V1
V4
II
aVL
V2
V5
III
aVF
V3
V6
V1
II

FIGURE - 1. A 12-LEAD EKG FROM A PATIENT WITH SUPRAVENTRICULAR TACHYCARDIA (HEART RATE =180* BEATS PER MINUTE)

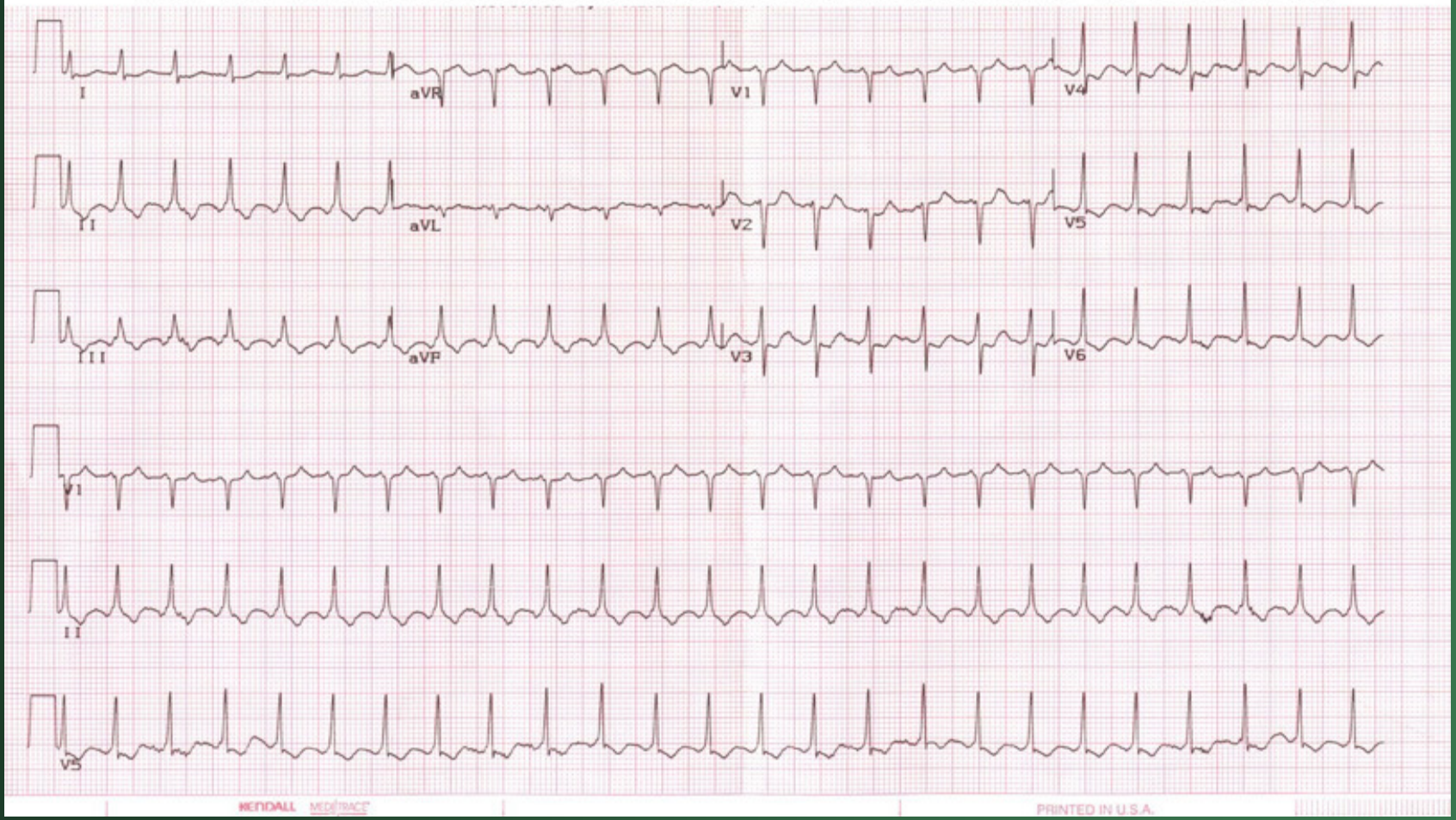

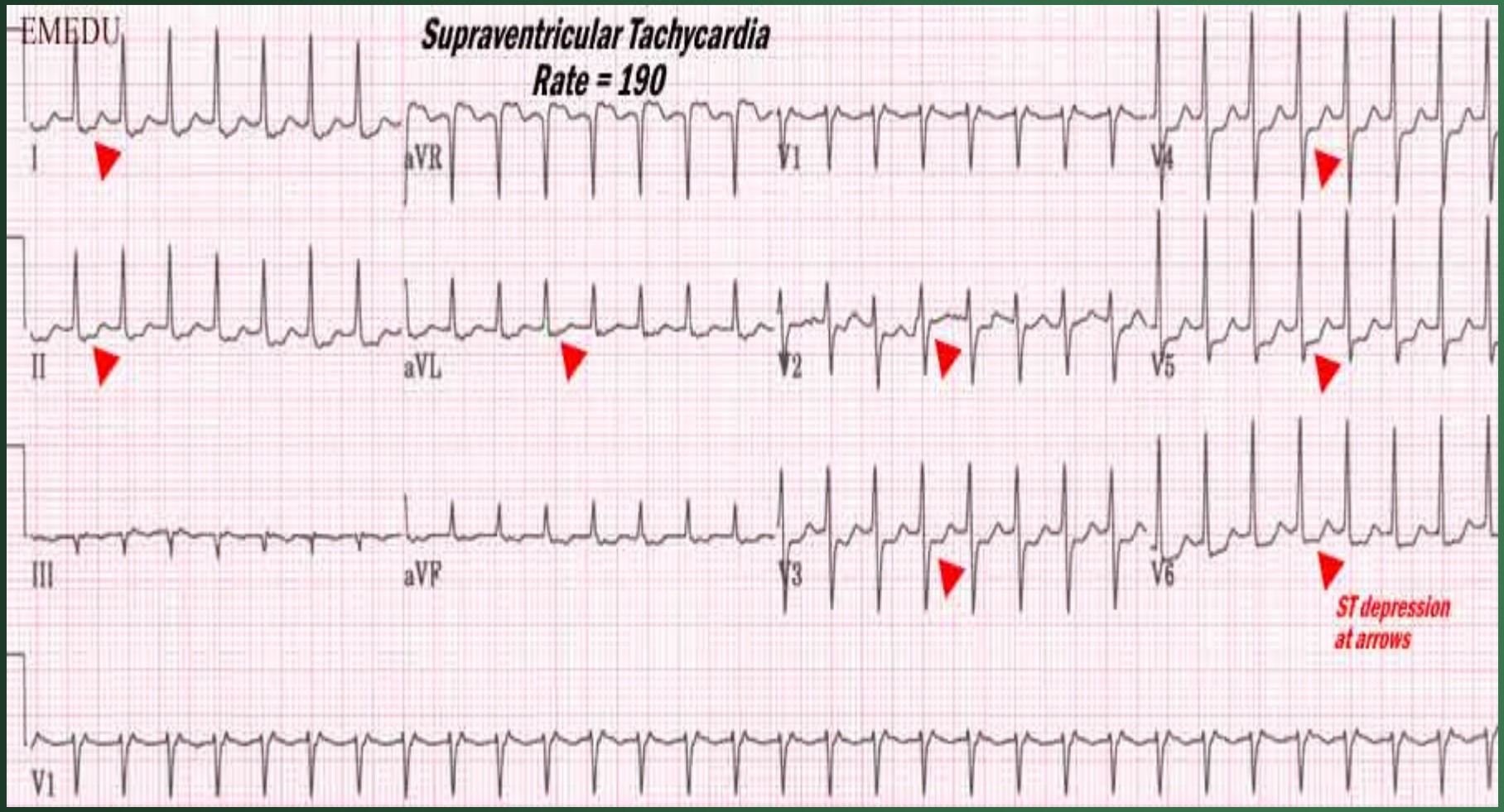
EMEDU
Supraventricular Tachycardia
Rate = 190
I
aVR
V1
V4
II
aVL
V2
V5
III
aVF
V3
V6
ST depression
at arrows
V1

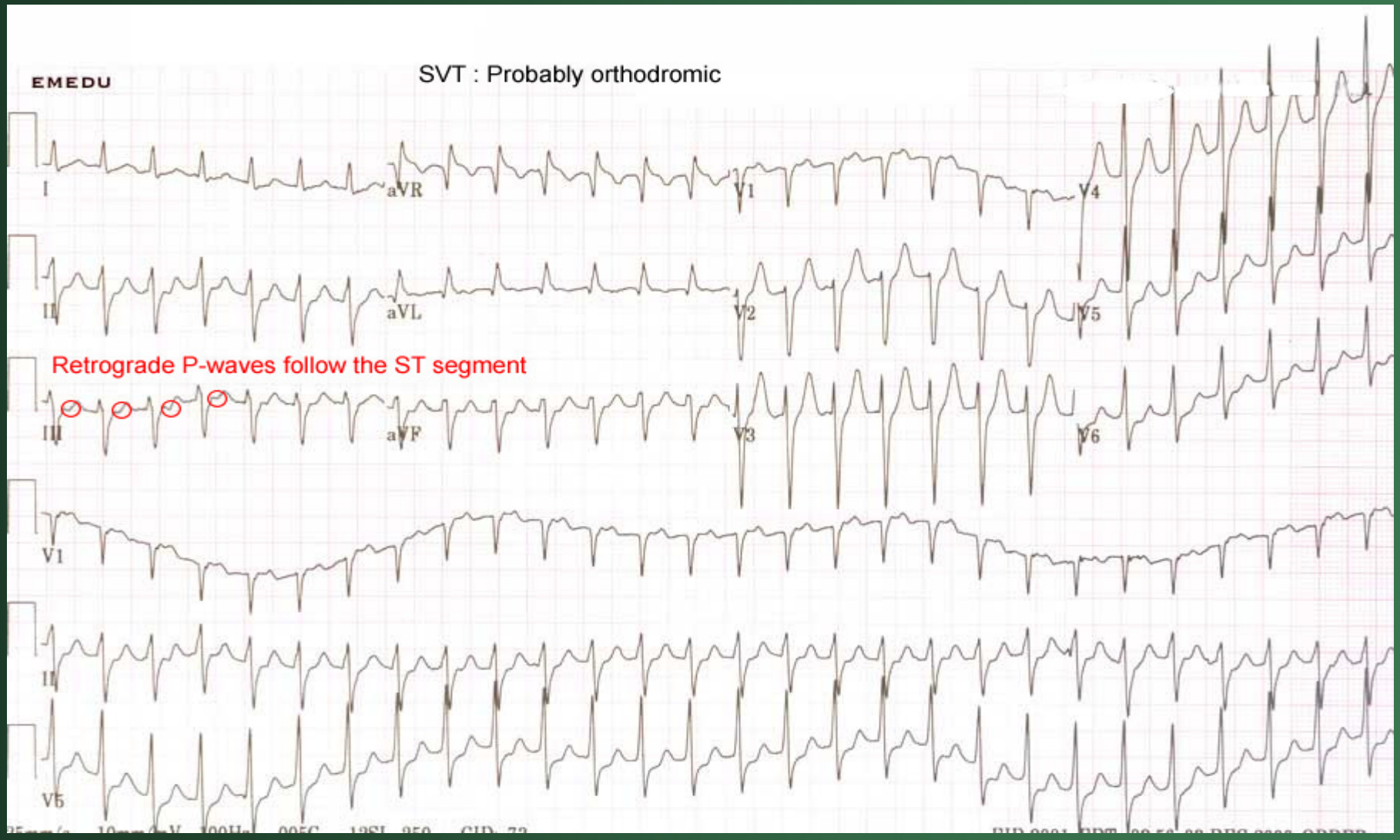
EMEDU
SVT : Probably orthodromic
I
aVR
V1
V4
II
aVL
V2
V5
Retrograde P-waves follow the ST segment
III
aVF
V3
V6
V1
II
V5

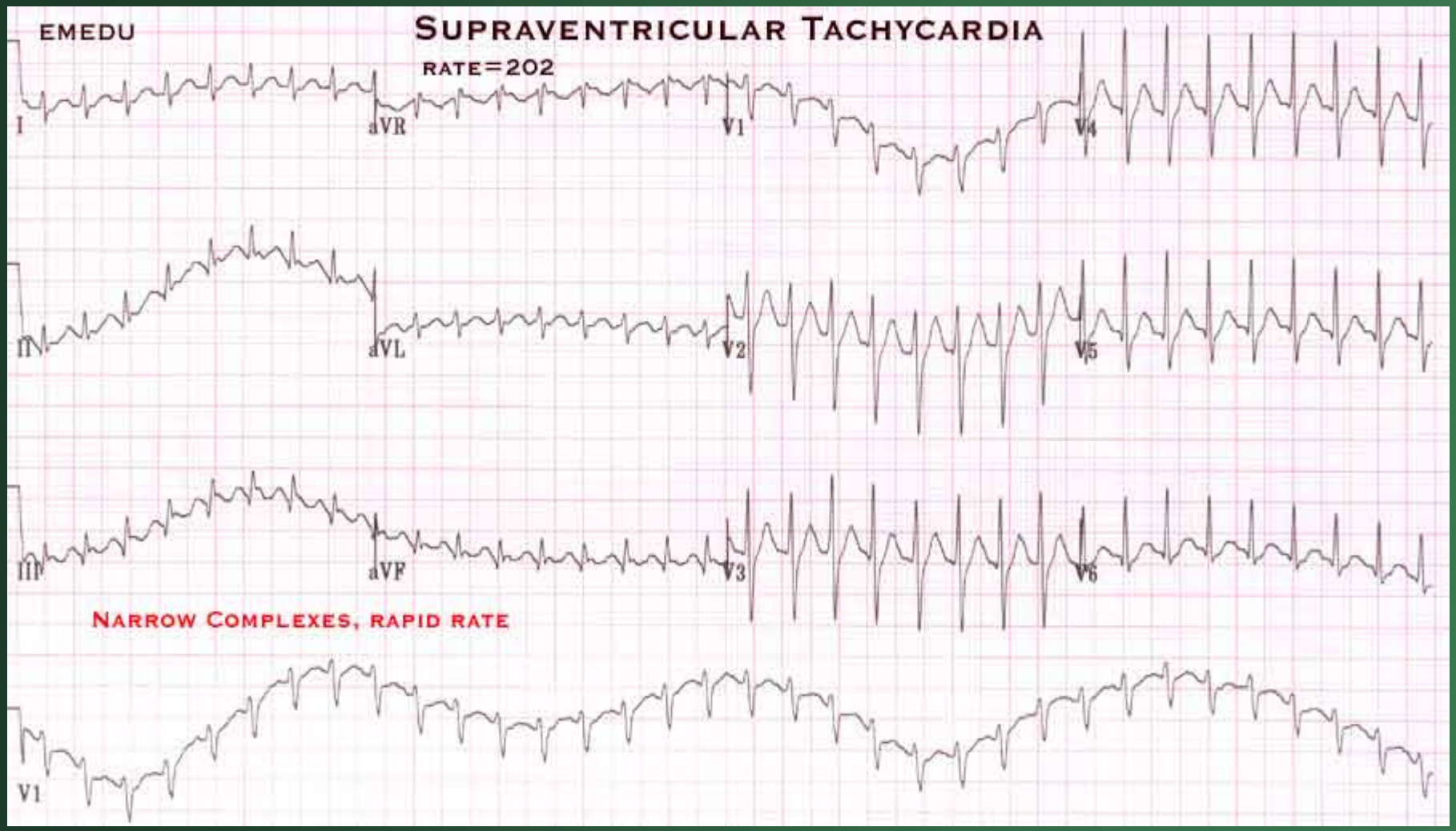
EMEDU
SUPRAVENTRICULAR TACHYCARDIA
RATE=202
I
aVR
V1
V4
II
aVL
V2
V5
III
aVF
V3
V6
NARROW COMPLEXES, RAPID RATE
V1

MAT

- Irregular
- P wave morphology different
- pulmonary disease
- Strain patterns
- Ischemic patterns
- Rx the pulmonary disease

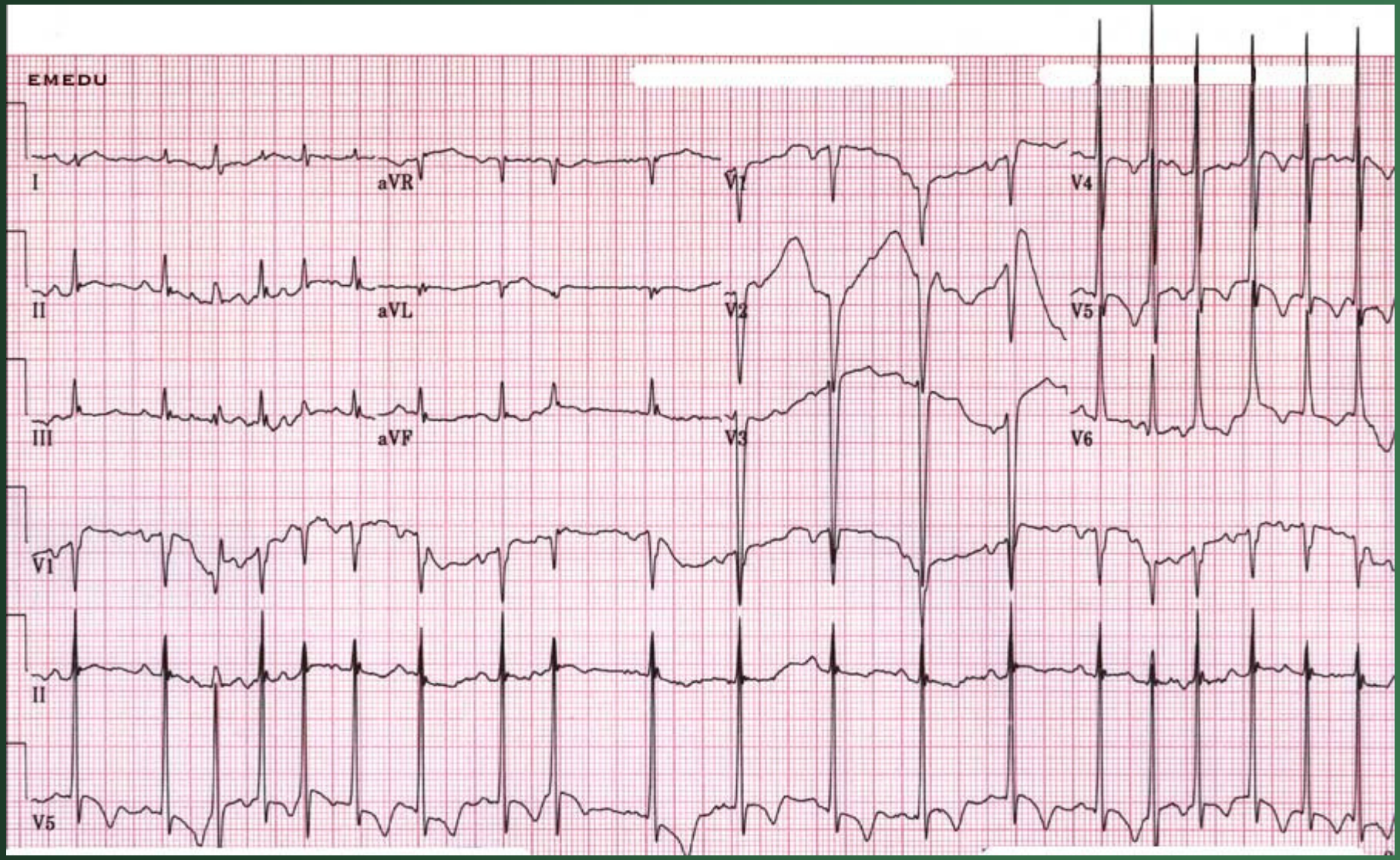
EMEDU
I
aVR
V1
V4
II
aVL
V2
V5
III
aVF
V3
V6
V1
II
V5

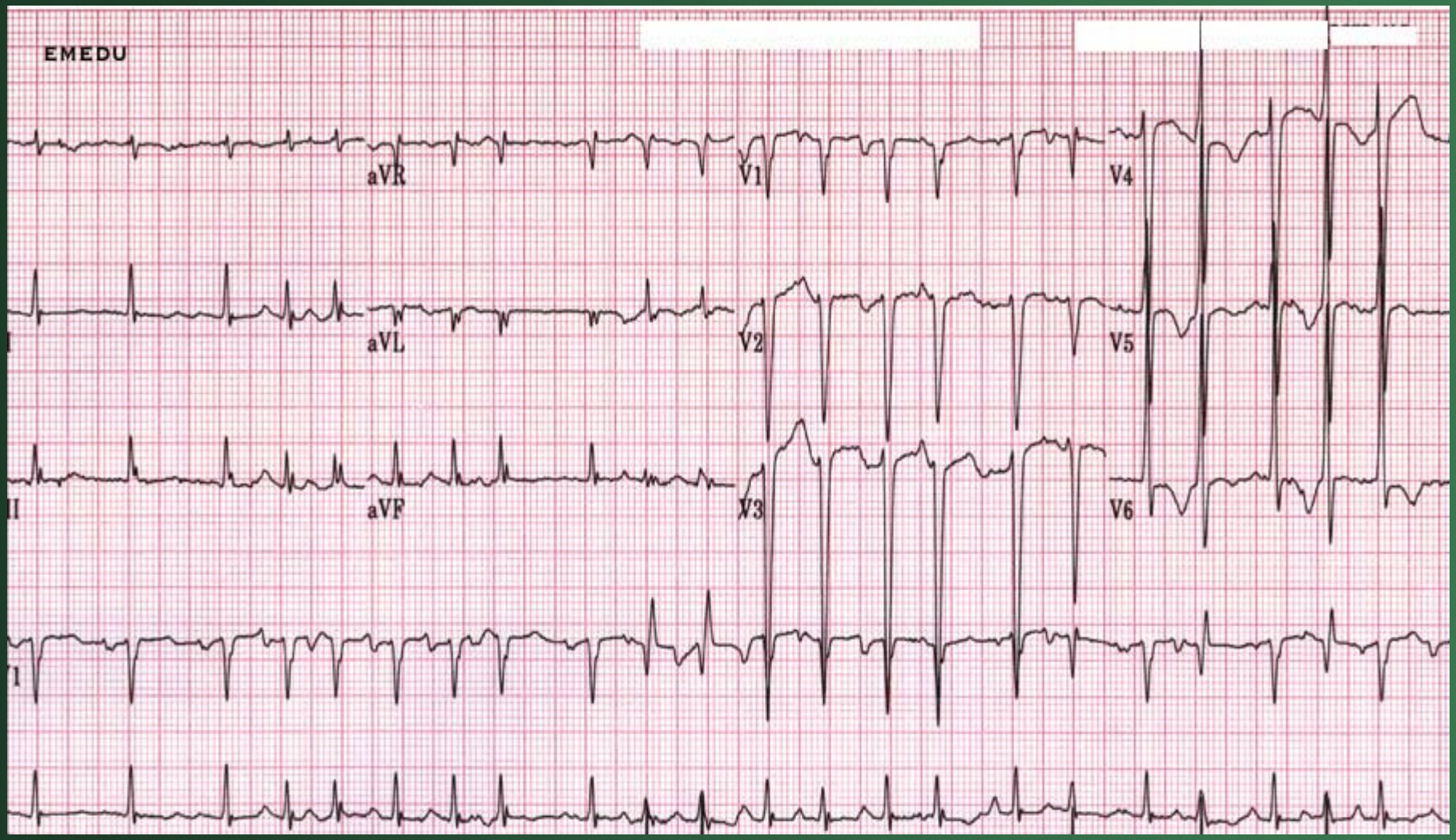
EMEDU
aVR
V1
V4
aVL
V2
V5
aVF
V3
V6

WPW

- Short p-r interval
- Delta wave
- Accessory pathway (BK) to bypass AVN
- Bouts of tachycardia

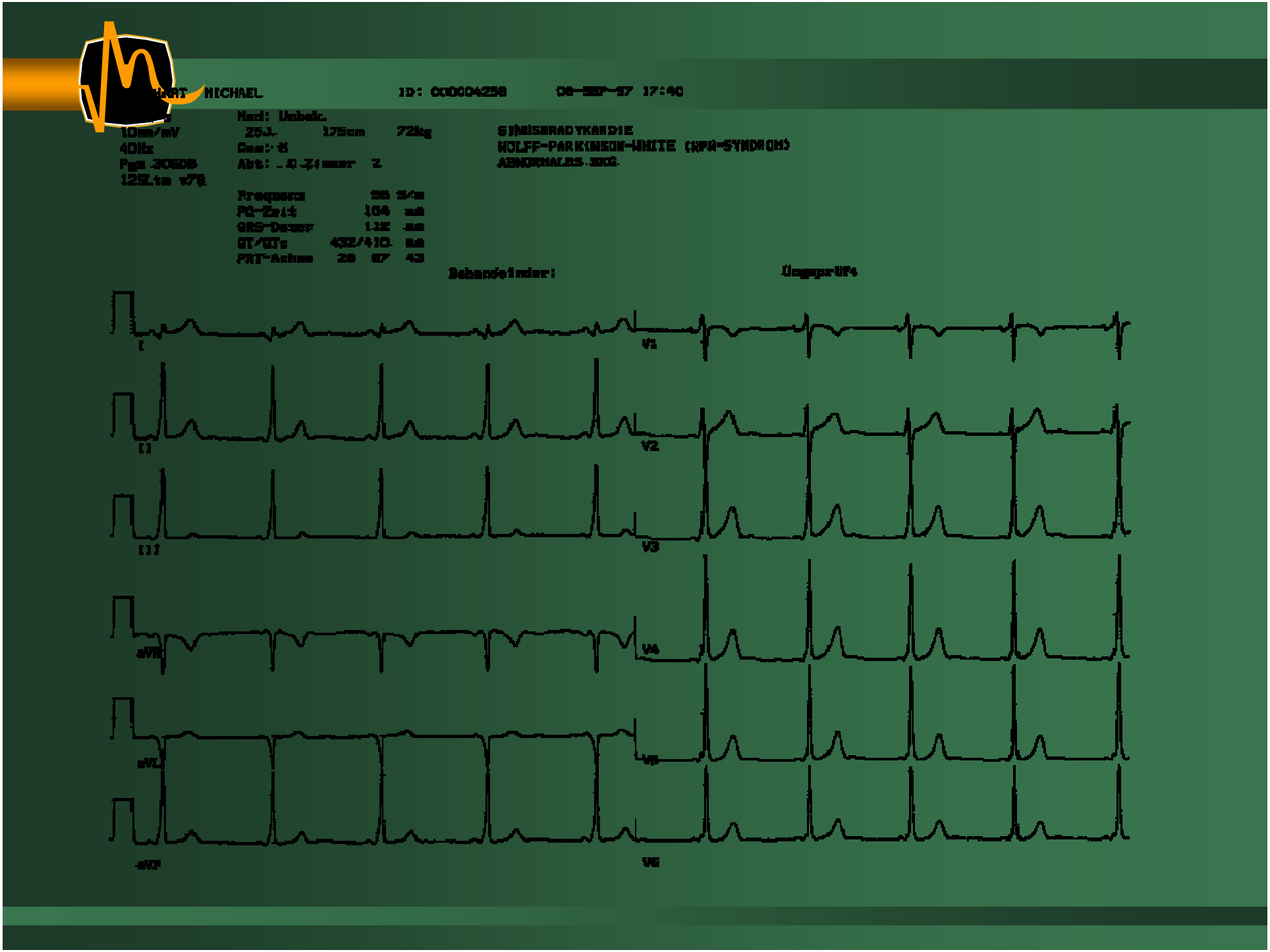
MICHAEL
ID: 000004258
17:40
Med: Unbek.
10mm/mV
40Hz
25J.
175cm
72kg
SINUSBRADYKARDIE
WOLFF-PARKINSON-WHITE (WPW-SYNDROM)
ABNORMALES EKG.
Frequenz
PQ-Zeit
QRS-Dauer
QT/QTs
PRT-Achse
Behandelnder:
Ungeprüft
I
II
III
aVR
aVL
aVF
V1
V2
V3
V4
V5
V6



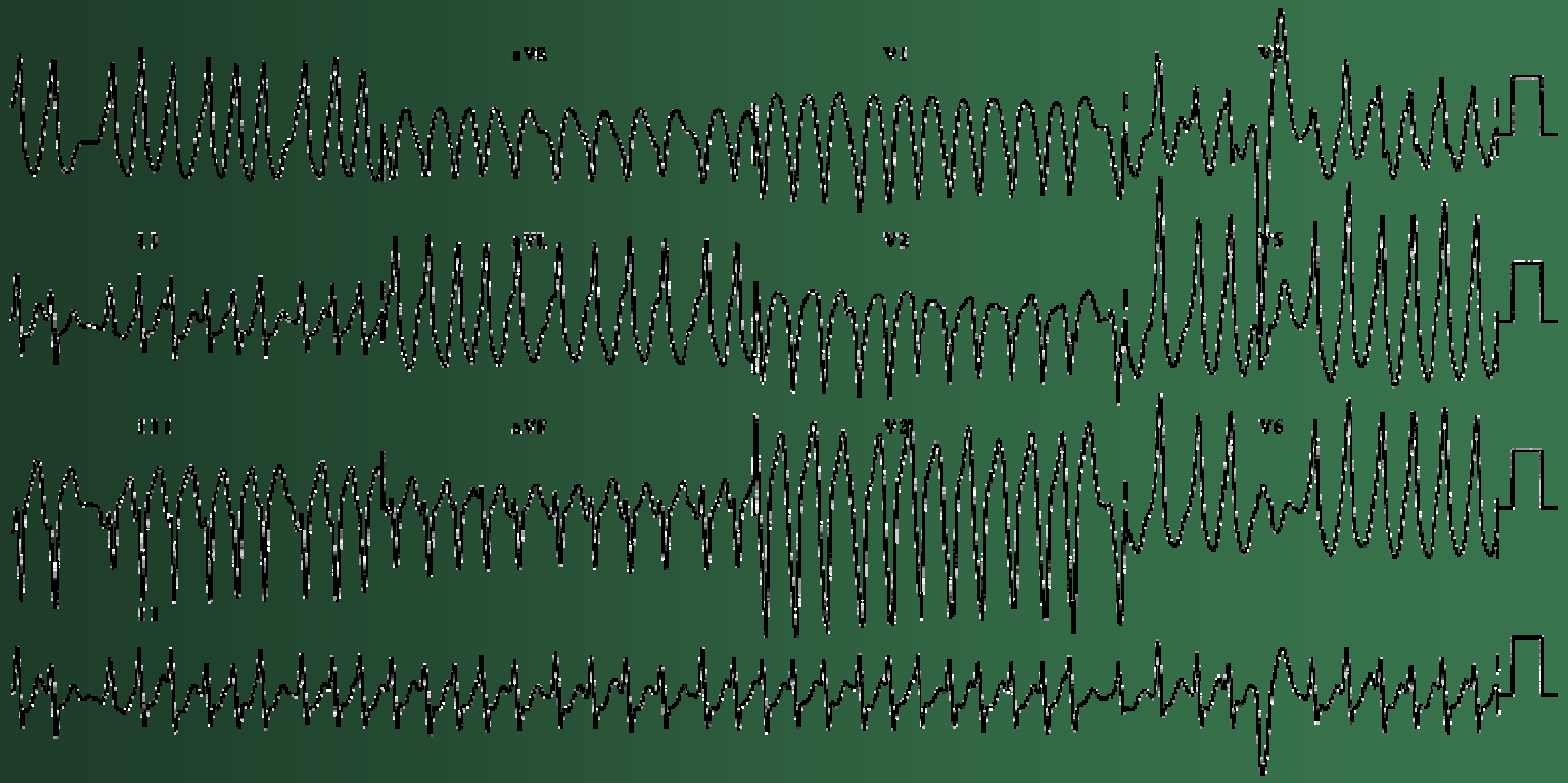

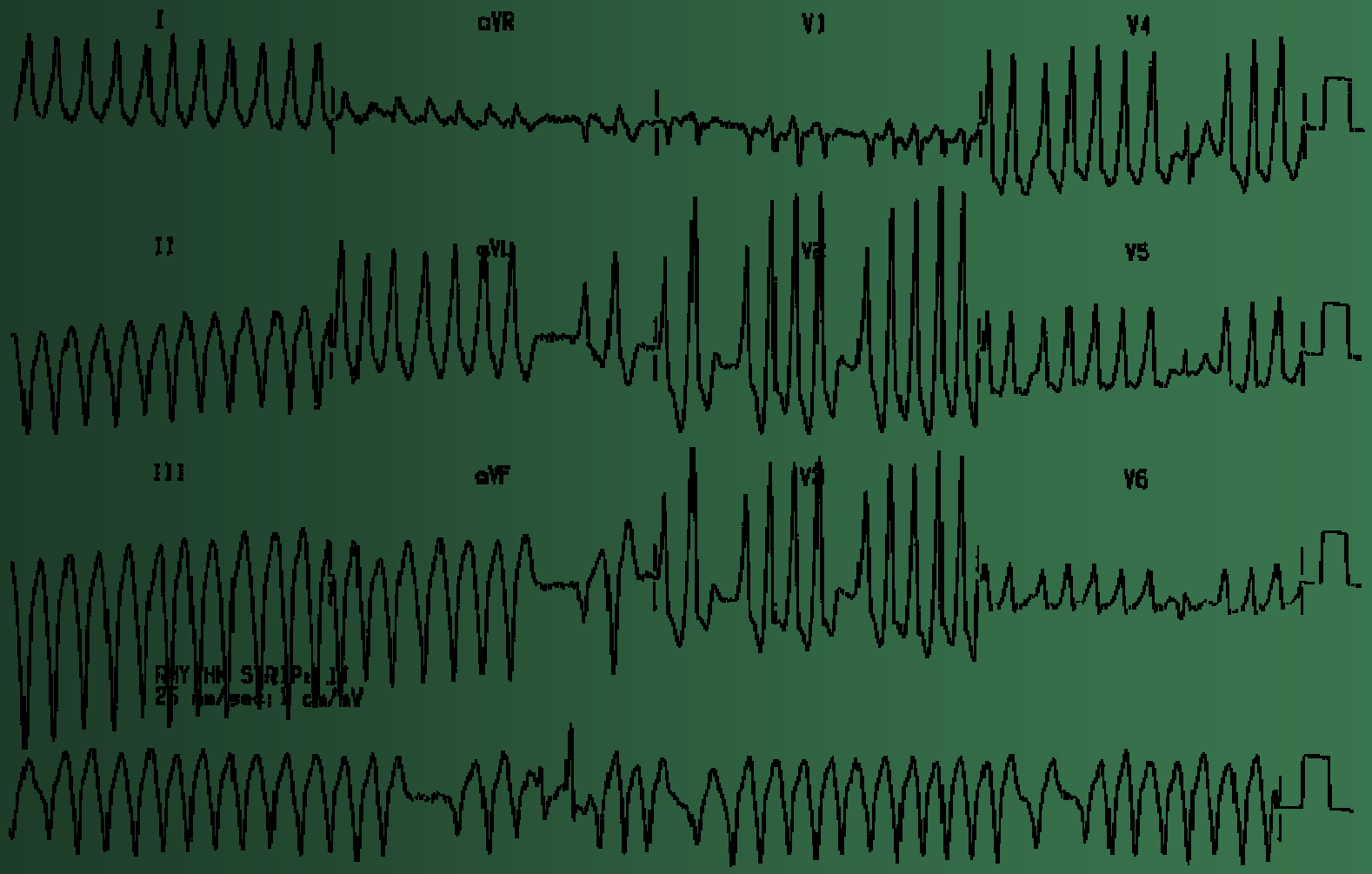
I
aVR
V1
V4
II
aVL
V2
V5
III
aVF
V3
V6
RHYTHM STRIP: II
25 mm/sec; 1 cm/mV

FOR GAWD'S SAKE, FRANK...
YOU'RE READING IT UPSIDE DOWN.
BERRY 75 ©



<u>References</u>

ACS Consultants, 12 lead ECG instructor course, Phalen 1995.

The 12 Lead ECG In Acute Myocardial Infarction, T. Phalen. Mosby 1996.

Berry, Steve. Cartoonist, C/S Co.

notanambulancedriver@aol.com

ecglibrary.com

webmd

emedu.org